

Learning and growing from misdiagnosis

羅東博愛醫院 病理科

施洽雯

105-8-14

國小時慘痛的錯誤至今仍記憶猶新

緣起



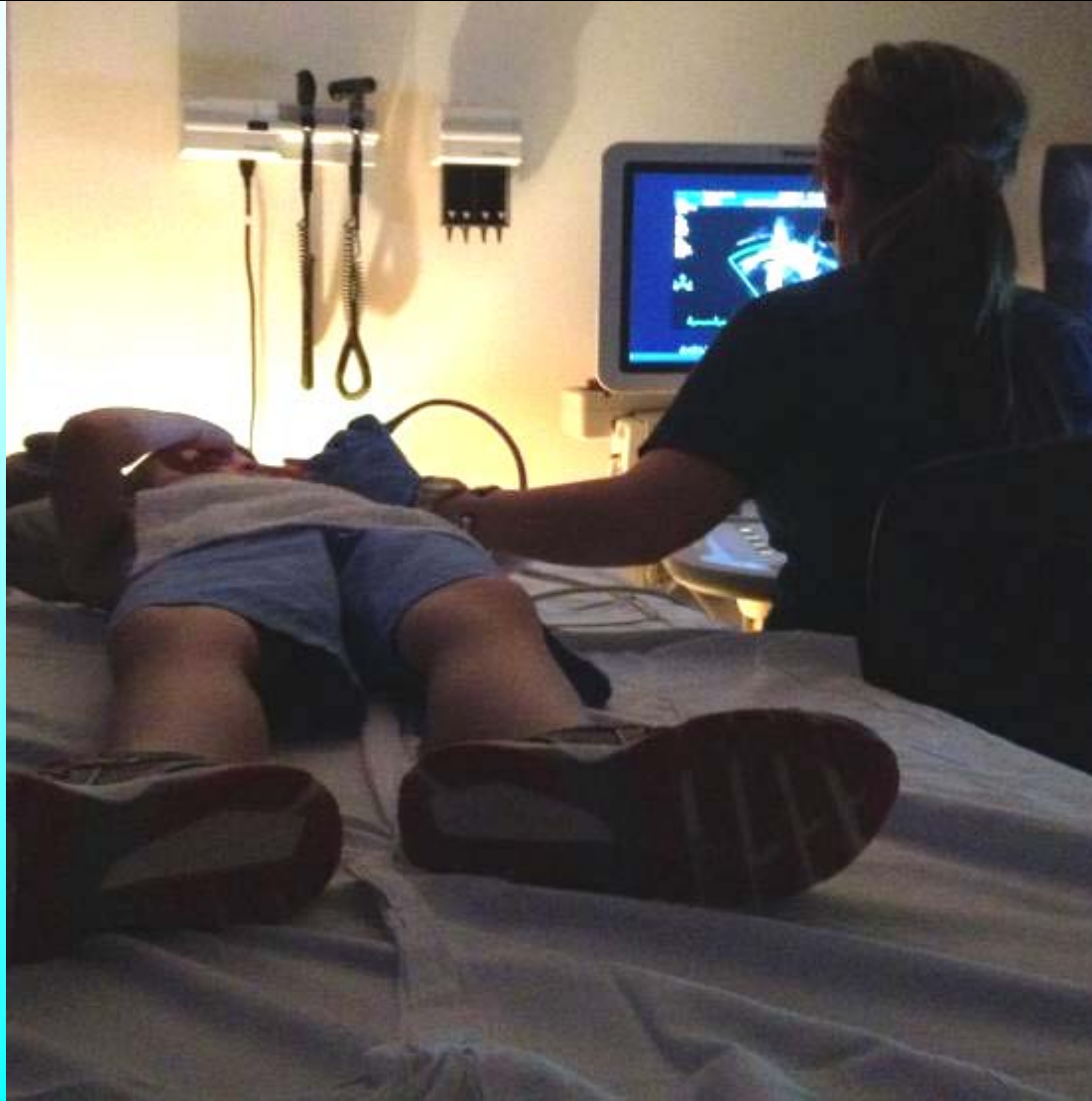國小時慘痛的錯誤至今仍記憶猶新

緣起




他登記他所做過的病例，追踪病理結果，
他知道他錯在那裡，他不斷精進成長，
終成為最有權威的超音波診斷教授。

緣
起

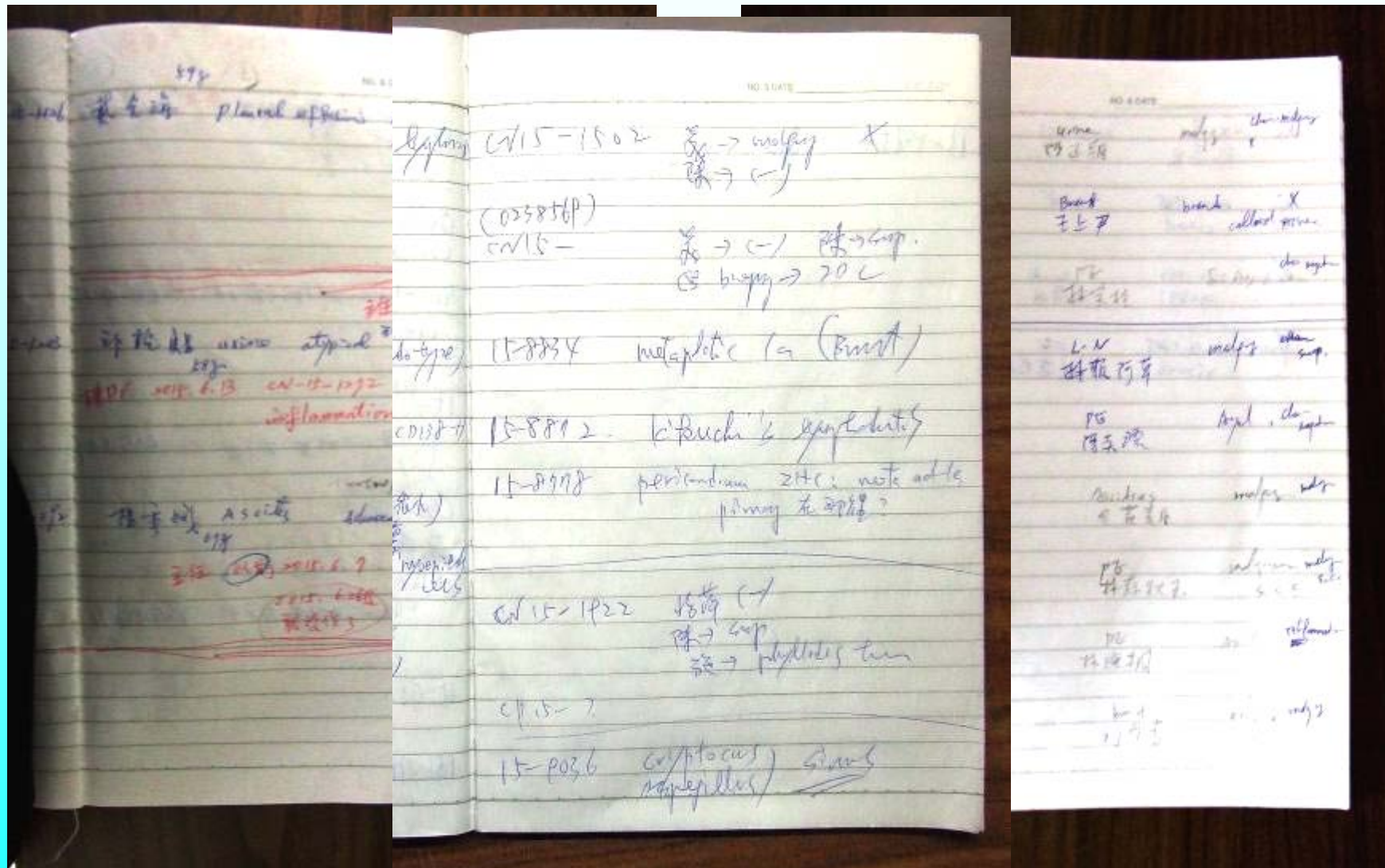


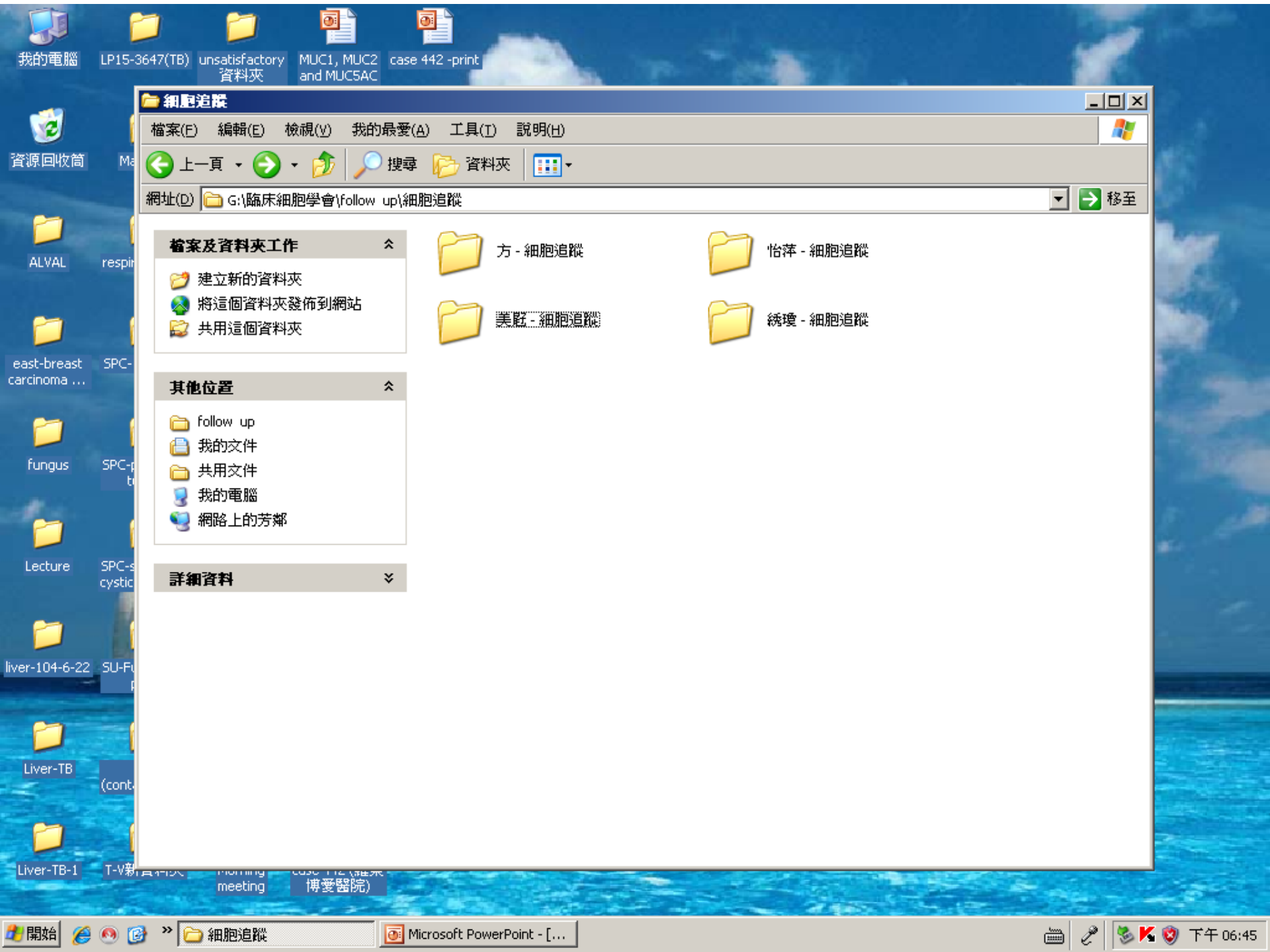


細胞病理追蹤登記本



細胞病理追蹤登記本





我的電腦 LP15-3647(TB) unsatisfactory 資料夾 MUC1, MUC2 and MUC5AC case 442 -print

資源回收筒

ALVAL respir

east-breast carcinoma ...

fungus SPC-p

Lecture SPC-s

liver-104-6-22 SU-Fu

Liver-TB (cont

Liver-TB-1 T-V新會

細胞追蹤

檔案(E) 編輯(E) 檢視(V) 我的最愛(A) 工具(T) 說明(H)

← 上一頁 → 搜尋 資料夾

網址(D) G:\臨床細胞學會\follow up\細胞追蹤 移至

檔案及資料夾工作

- 建立新的資料夾
- 將這個資料夾發佈到網站
- 共用這個資料夾

- 方 - 細胞追蹤
- 怡萍 - 細胞追蹤
- 美群 - 細胞追蹤
- 綉瓊 - 細胞追蹤

其他位置

- follow up
- 我的文件
- 共用文件
- 我的電腦
- 網路上的芳鄰

詳細資料

檔案及資料夾工作

- 建立新的資料夾
- 將這個資料夾發佈到網站
- 共用這個資料夾

其他位置

- 細胞追蹤
- 我的文件
- 共用文件
- 我的電腦
- 網路上的芳鄰

詳細資料

104-1月細胞追蹤-怡萍
71 KB
Microsoft Word 文件

104-4月細胞追蹤-怡萍
71 KB
Microsoft Word 文件

104-7月細胞追蹤-怡萍
71 KB
Microsoft Word 文件

104-2月細胞追蹤-怡萍
71 KB
Microsoft Word 文件

104-5月細胞追蹤-怡萍
71 KB
Microsoft Word 文件

104-8月細胞追蹤-怡萍
71 KB
Microsoft Word 文件

104-3月細胞追蹤-怡萍
71 KB
Microsoft Word 文件

104-6月細胞追蹤-怡萍
71 KB
Microsoft Word 文件



RESULTS:

- A total of 88 swabbed biopsies were collected.
- The percentage of staining using the...

RESULTS:

- A total of 88 swabbed biopsies were collected.
- The percentage of staining using the...

104-06-細胞追蹤 [儲存模式] - Microsoft Word

Times New Roman - 12

細胞病理追蹤結果——104年06月

序號	細胞編號	病歷號	姓名	檢體別	醫檢師報告	病理醫師診斷
1-	CN15-1231	0114108	陳振雄	Pleural Effusion	Malignancy-(Meta-Adeno)	Malignancy-(Meta Adeno) 陳醫師
2-	CN15-1241	0114108	陳振雄	Pleural Effusion	Malignancy-(Meta-Adeno)	Malignancy-(Meta Adeno) 陳醫師
3-	CN15-1244	0069359	楊秀娥	Cell block	Malignancy	Malignancy-(Meta Adeno) 陳醫師
	LP1505733			Adenocarcinoma		陳主任

頁面 1 / 4 字數 167 英文(美國) 簡體



細胞病理追蹤結果---104年7月

序號	細胞編號	病歷號	姓名	檢體別	醫檢師報告	病理醫師診斷
1	CN15-1412	328030	林文華	breast	malignancy	malignancy 陳醫師
	LP15-8167	Malignancy (ILC)				
2	CN15-1415	672976	張嵐綺	breast	suspicious	malignancy 陳醫師
	LP15-8575	Breast cancer (IDC)				
3	CN15-1457	593701	何枝炎	sputum	Atypical	atypical suspicious malignancy
4	CN15-1489	952072	吳志津	LN (axillary)	malignancy	malignancy
	LP15-8603	Breast cancer (IDC)				
5	CN15-491	895024	張進財	PE	malignancy	Negative 陳醫師

Review of cytology



細胞病理追蹤結果---104年7月。

序號	細胞編號	病歷號	姓名	檢體別	醫師報告	病理醫師診斷
1.	CN15-1412	328030	林文華	breast	malignancy	malignancy 陳醫師
	LP15-8167	Malignancy (ILC)				
2.	CN15-1415	672976	張淑純	breast	suspicious	malignancy 陳醫師
	LP15-8575	Breast cancer (IDC)				
3.	CN15-1457	593701	何枝英	spuhum	Atypical	atypical- suspicious malignancy
4.	CN15-1489	952072	吳志津	LN (axillary)	malignancy	malignancy
	LP15-8603	Breast cancer (IDC)				
5.	CN15-491	895024	張逸財	PF	malignancy	Negative 陳醫師

檢討錯誤不是責怪,而是要從錯誤中學習



你針對這病例做檢討
並做成報告



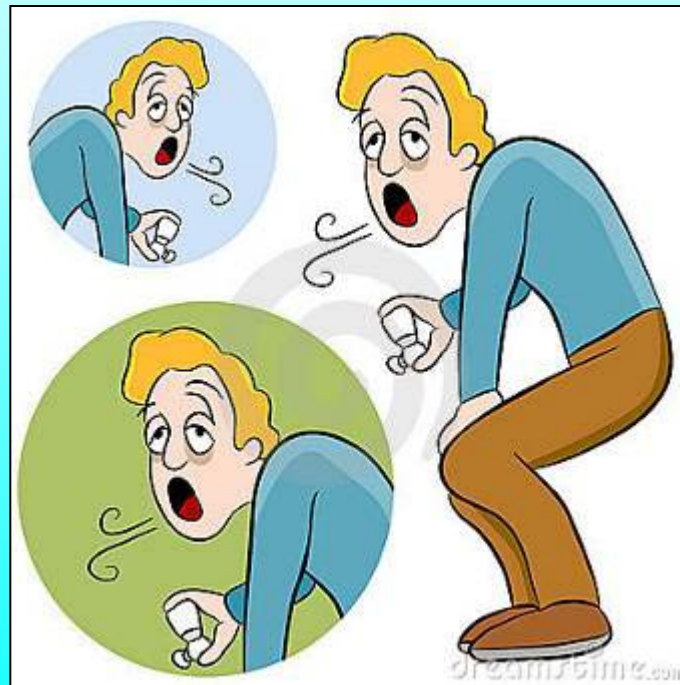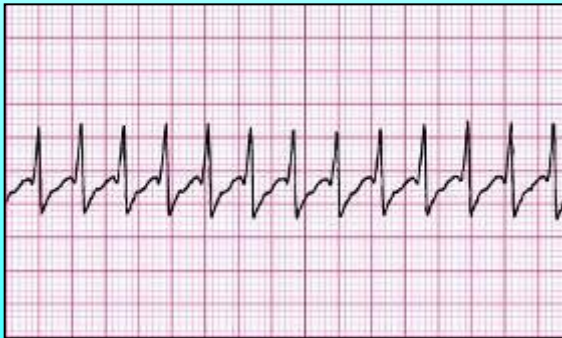
細胞病理研討會

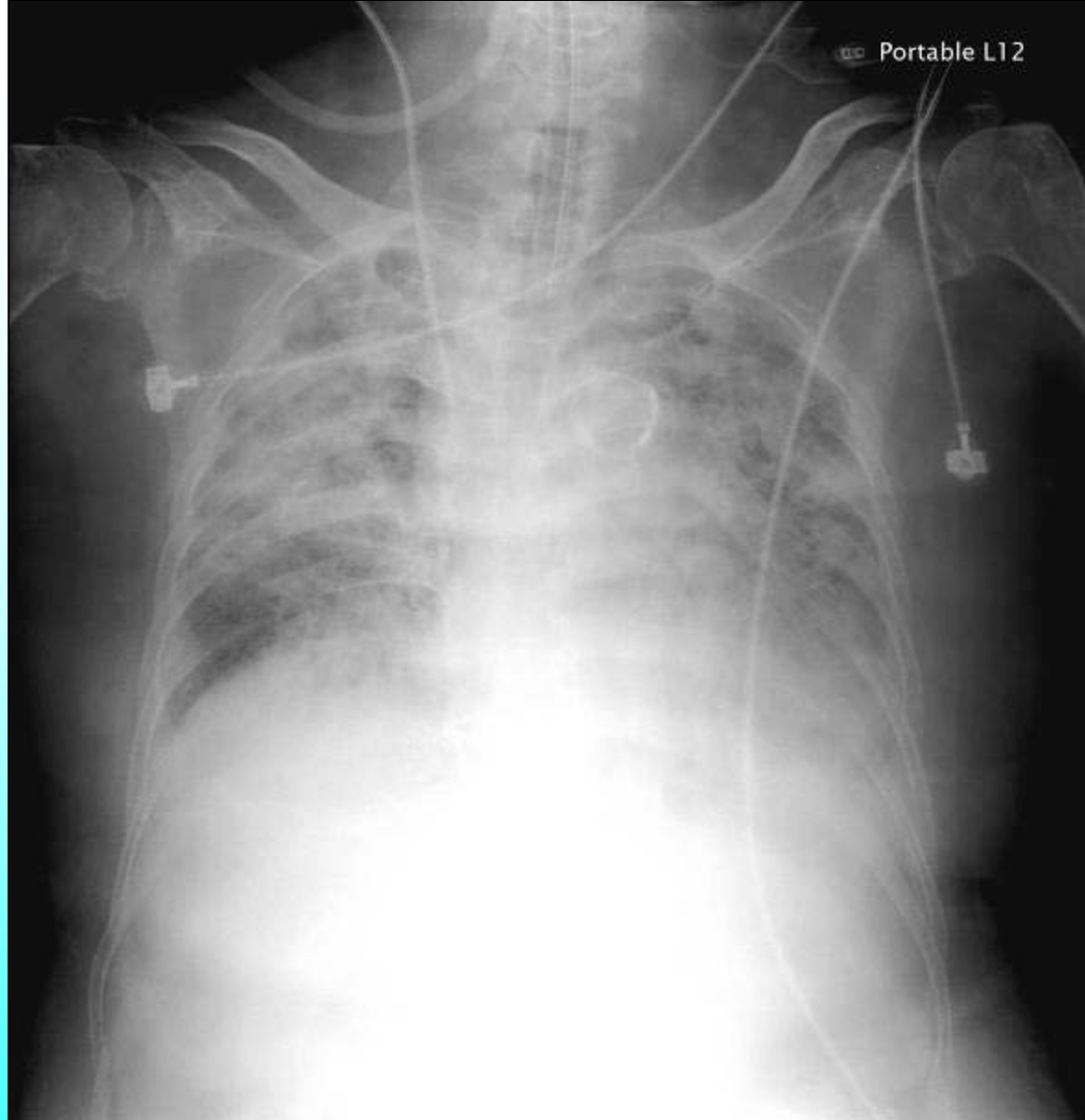
報告者：曾美慰

Case Report

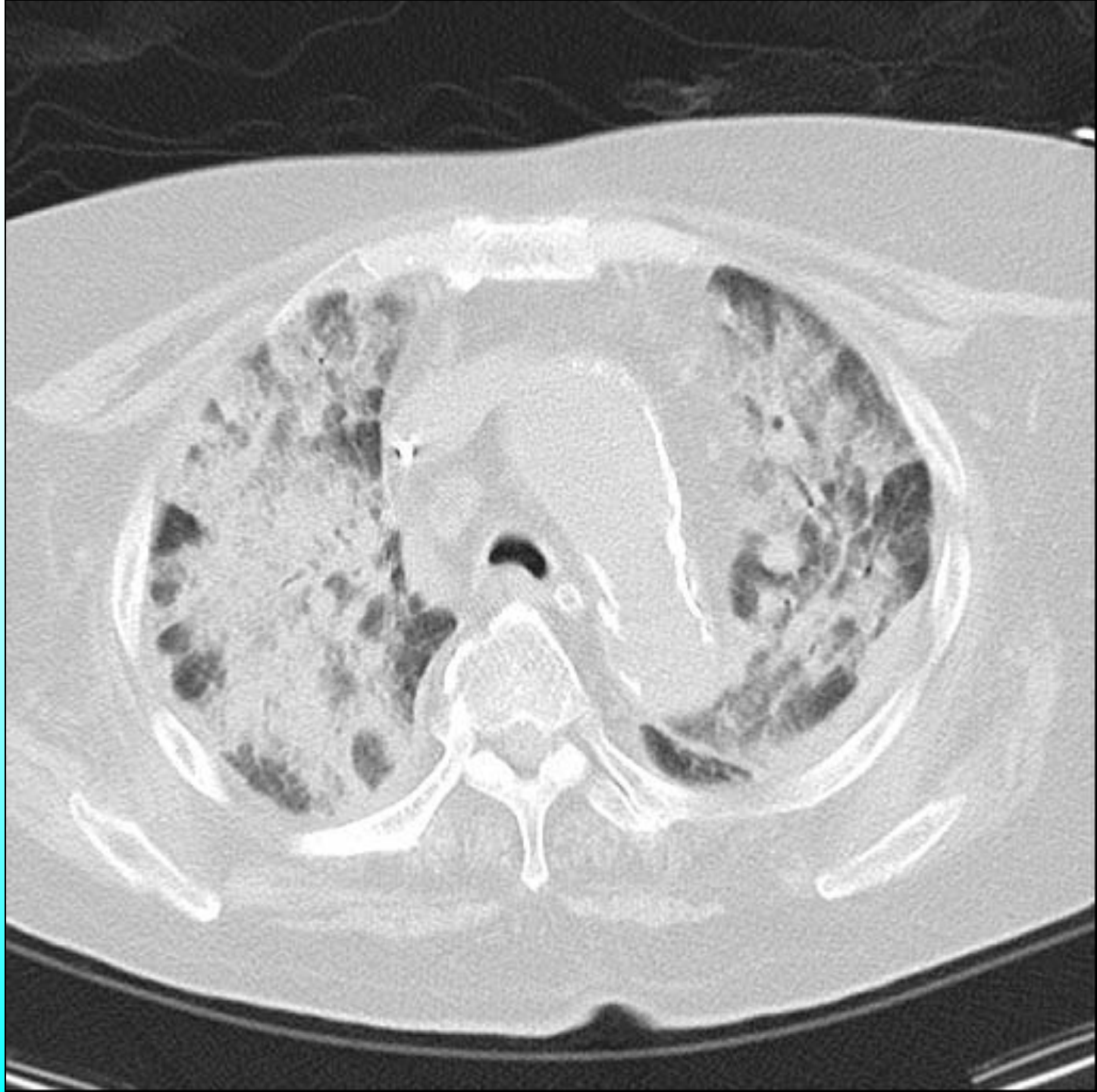
Clinical history:

A 78 year old woman was admitted to our hospital because of tachycardia, cough with sputum, progressive dyspnea and fever.



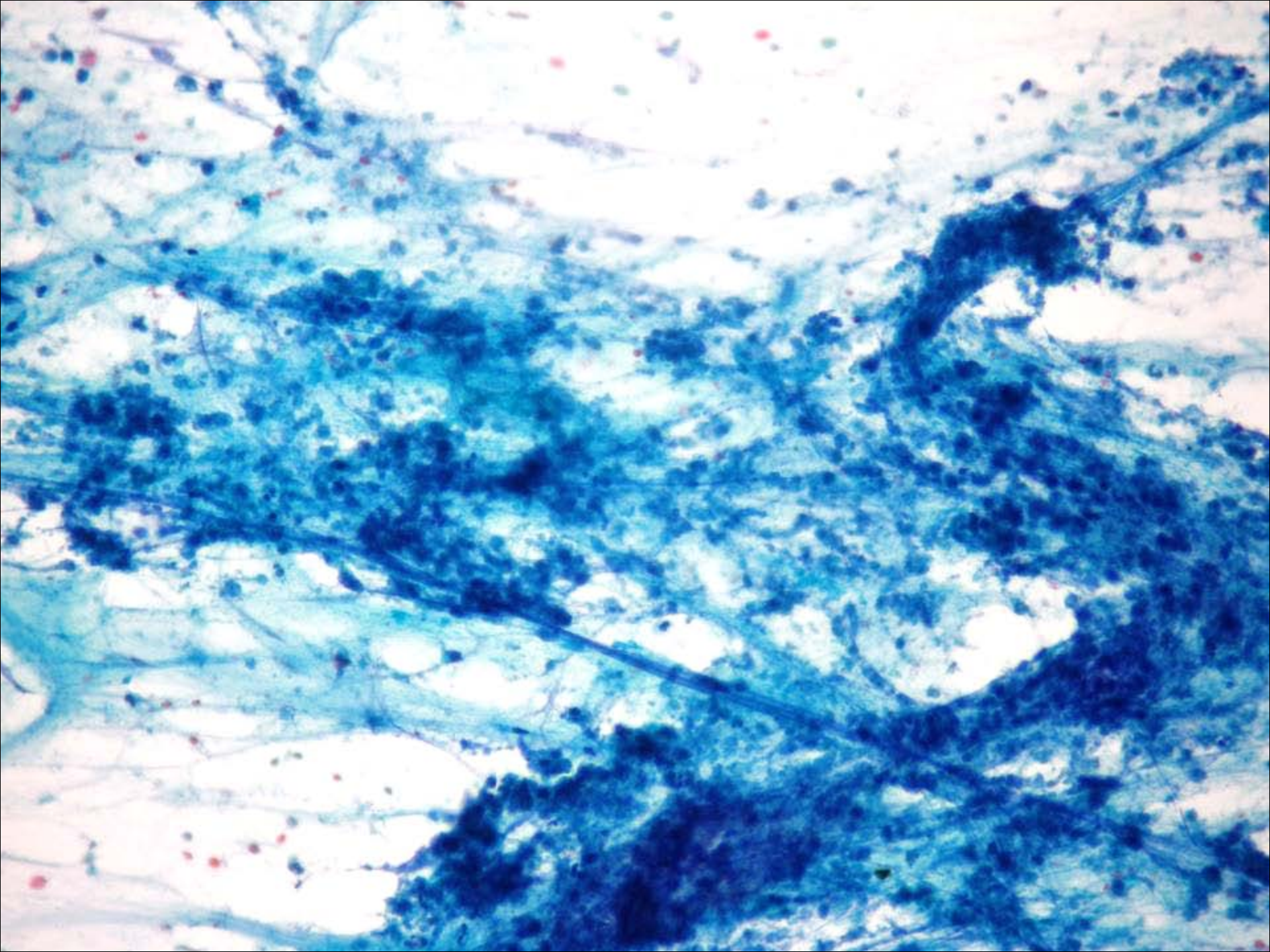


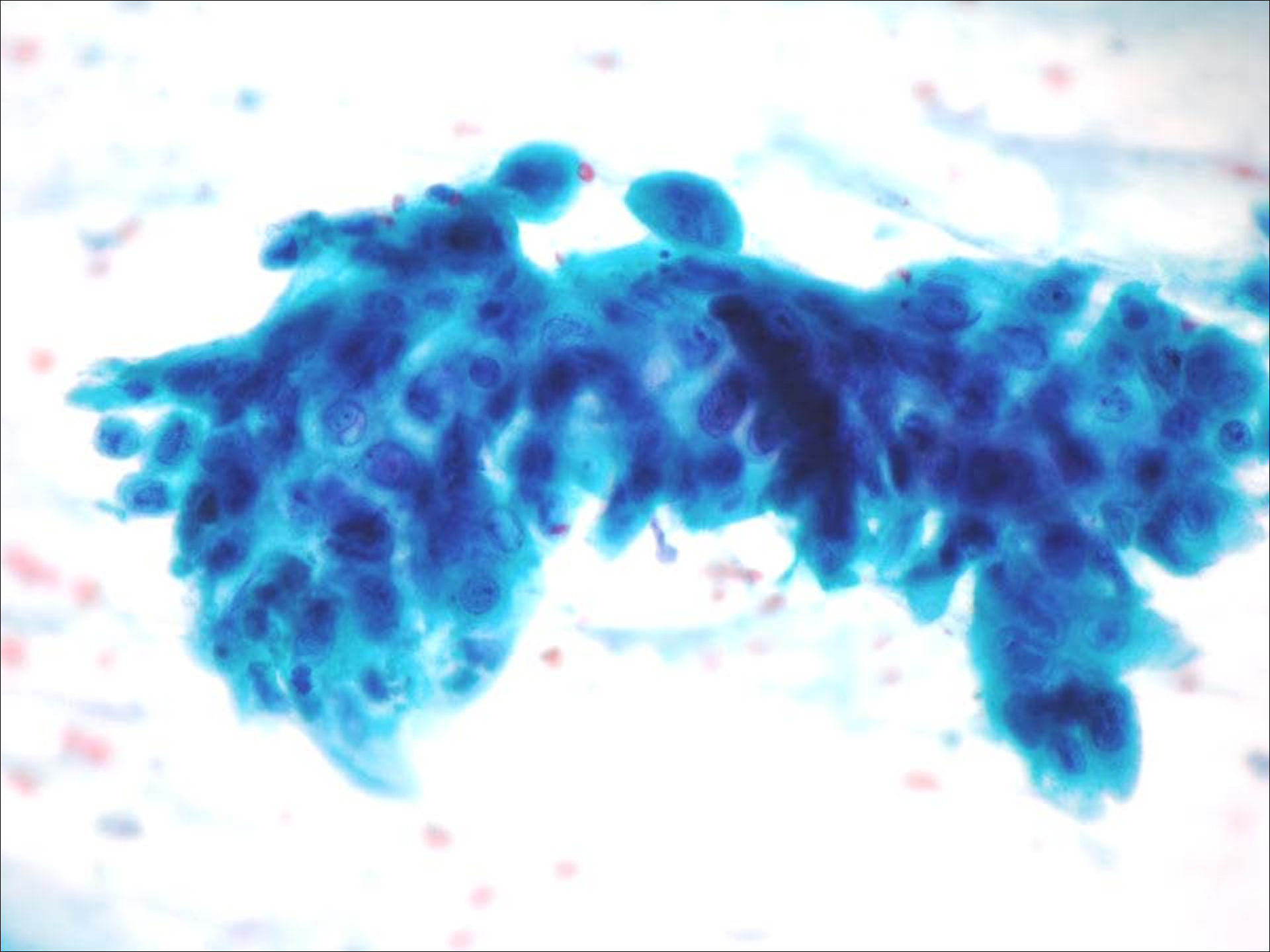
Chest X-ray showed interstitial and alveolar infiltrates in the both lung.

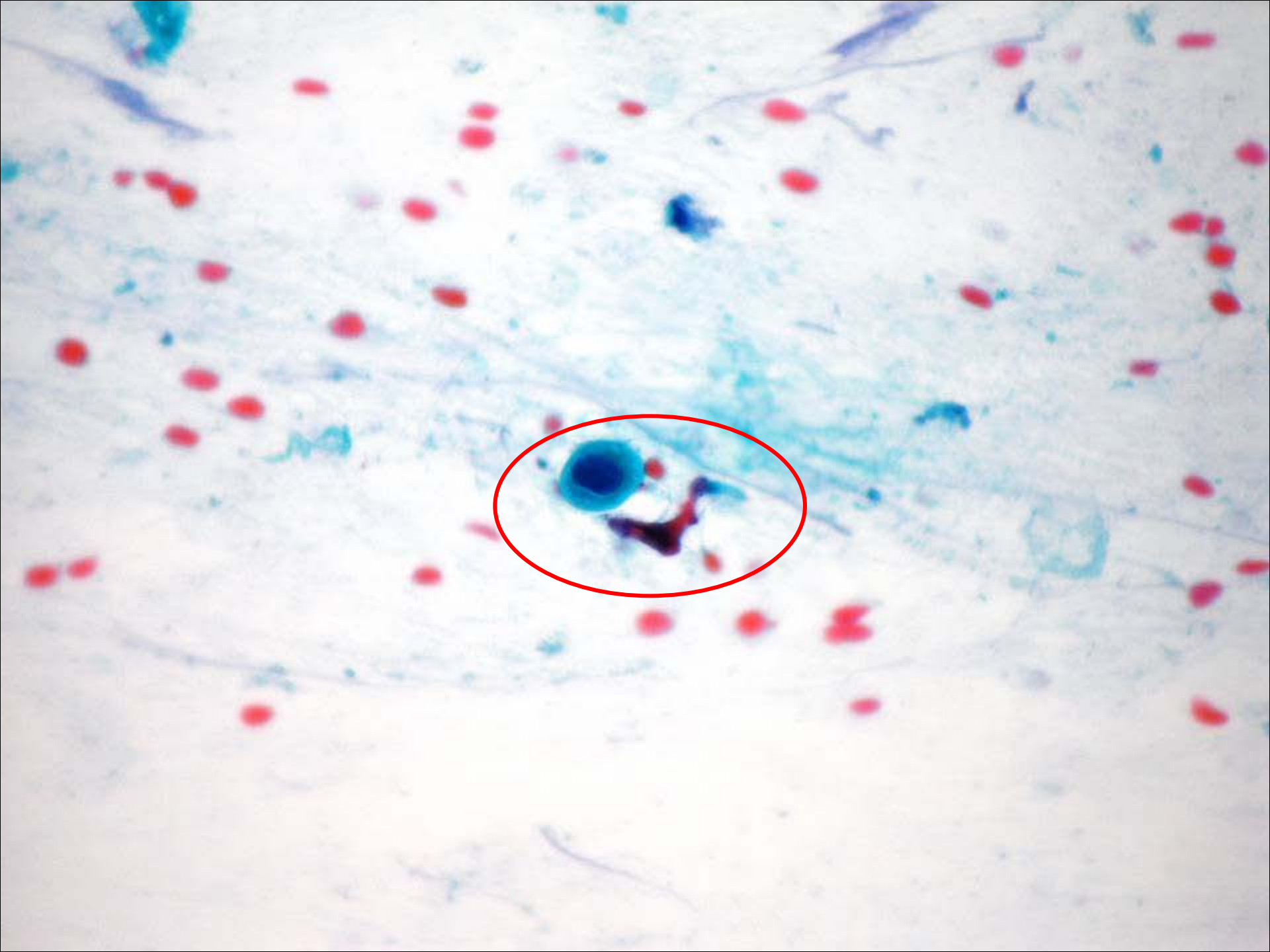


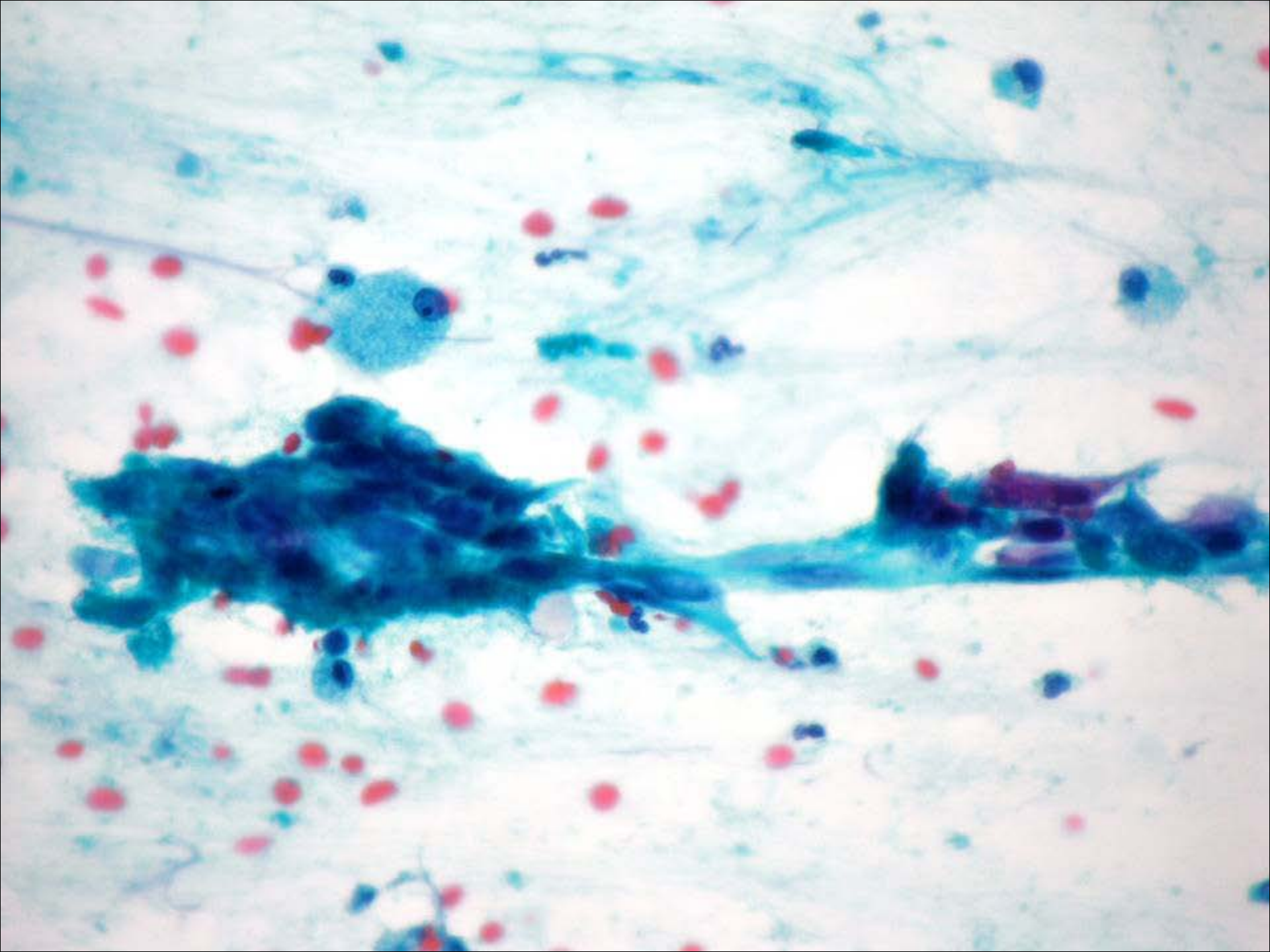
- **Sputum cytology was performed:**

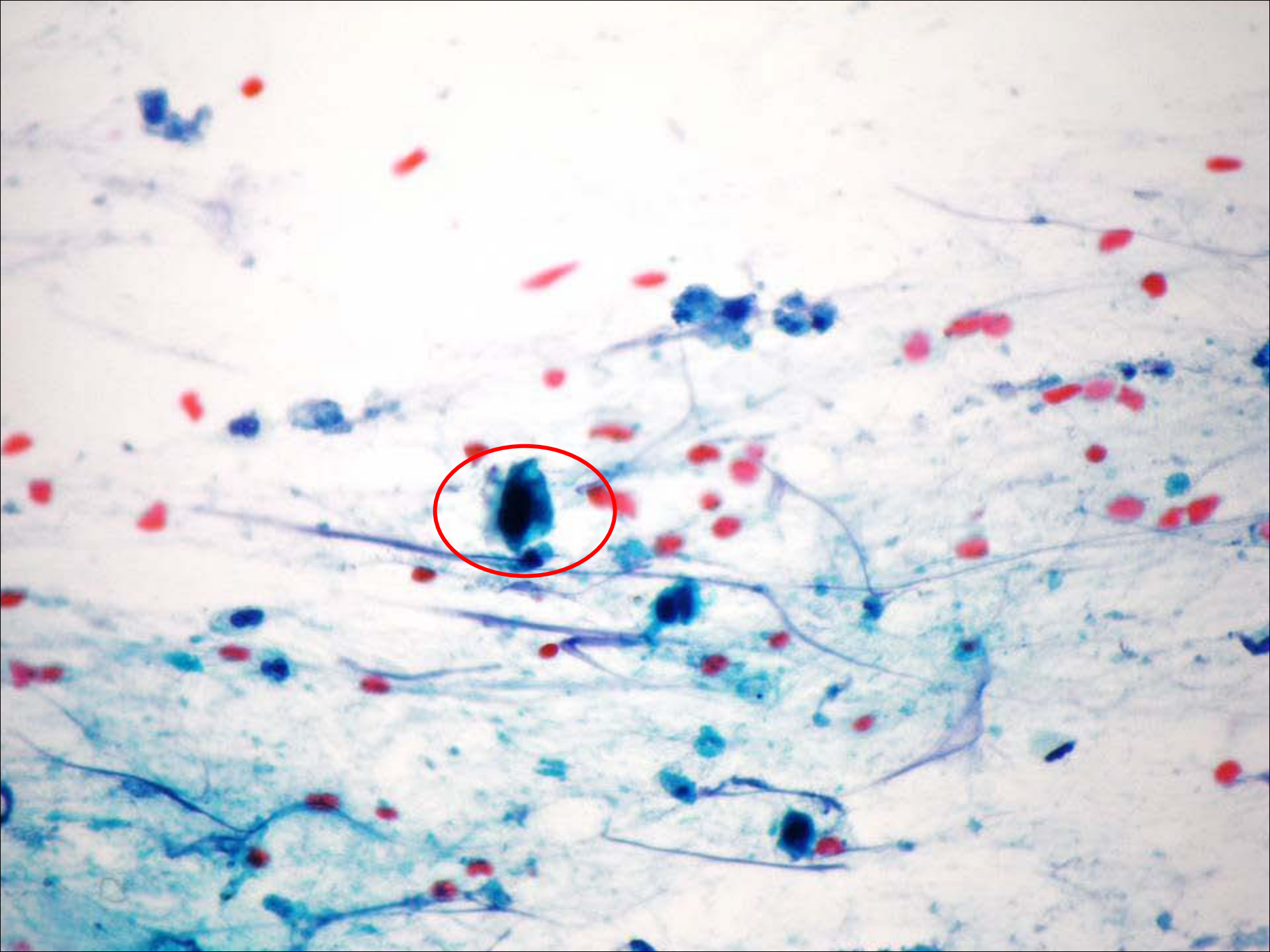
2014-12-19 , 2014-12-20 , 2014-12-21

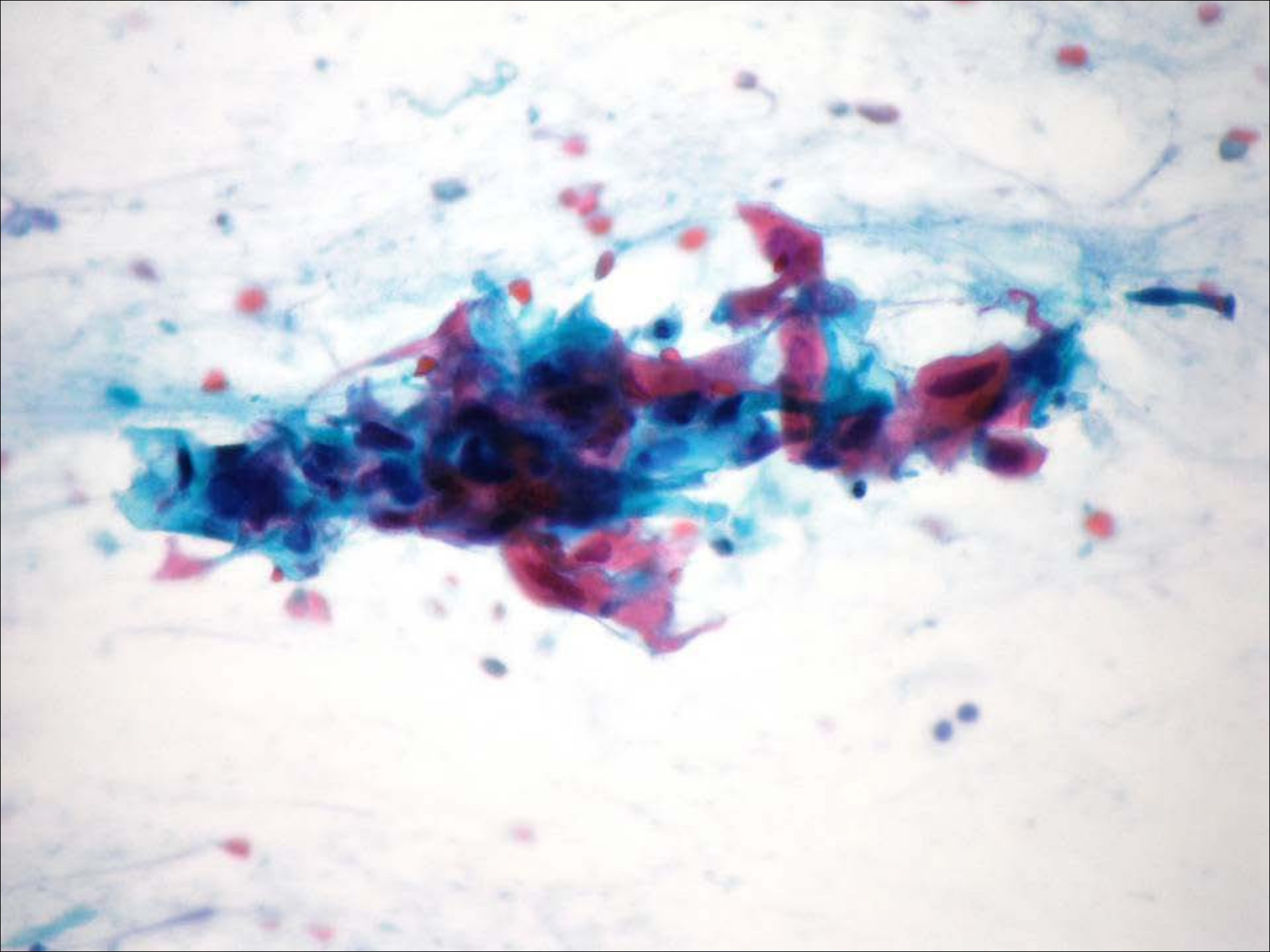


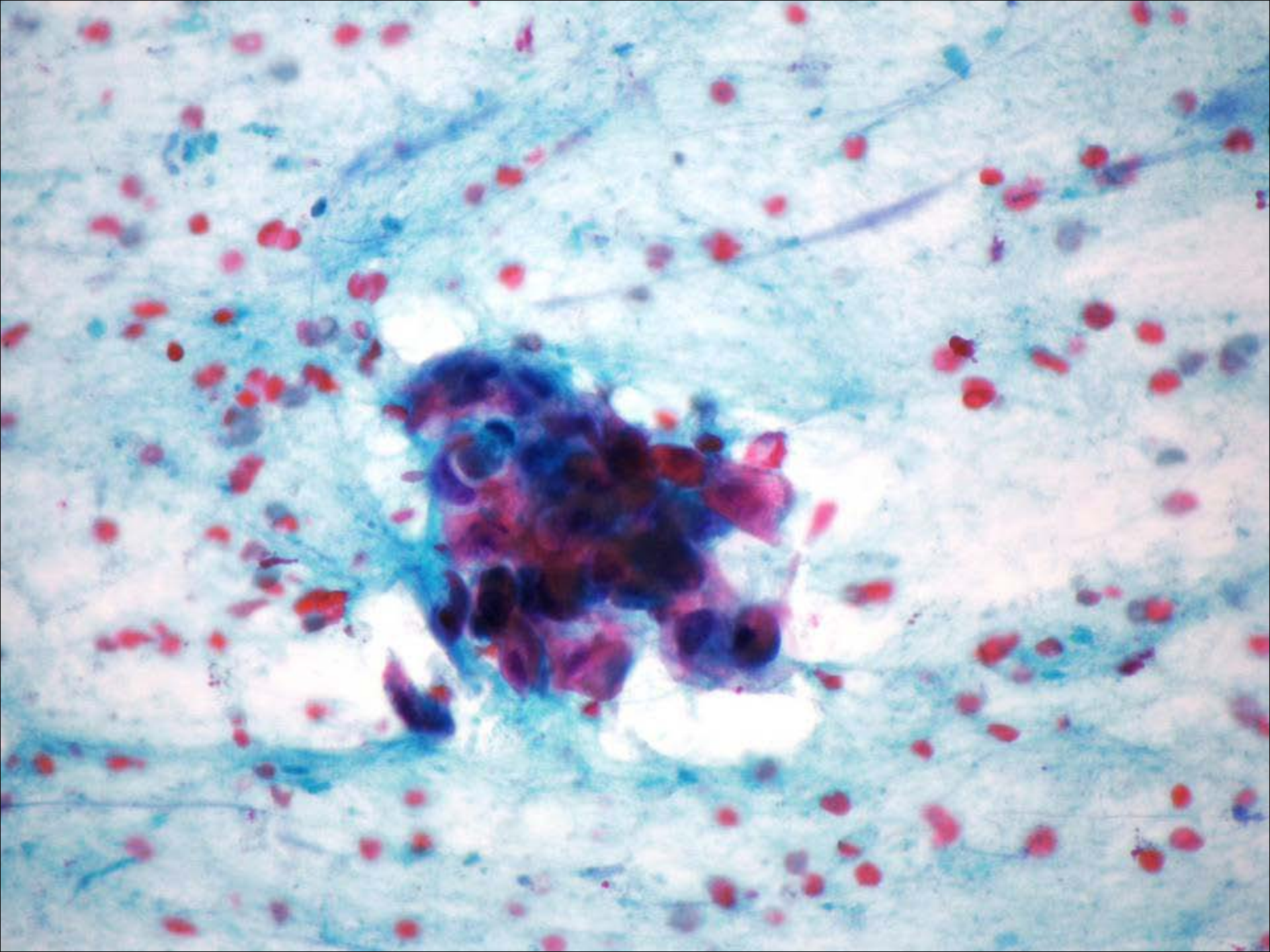


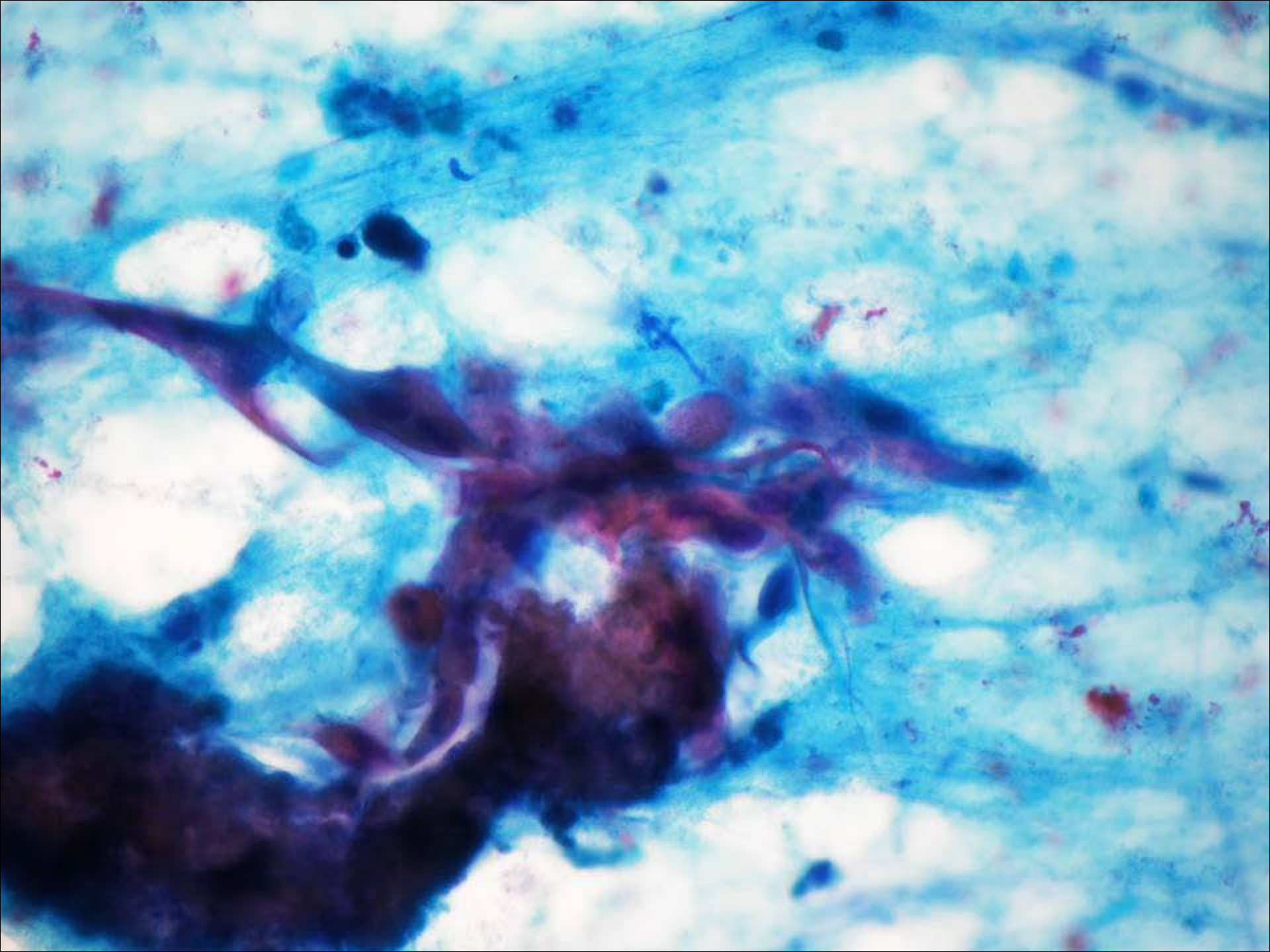


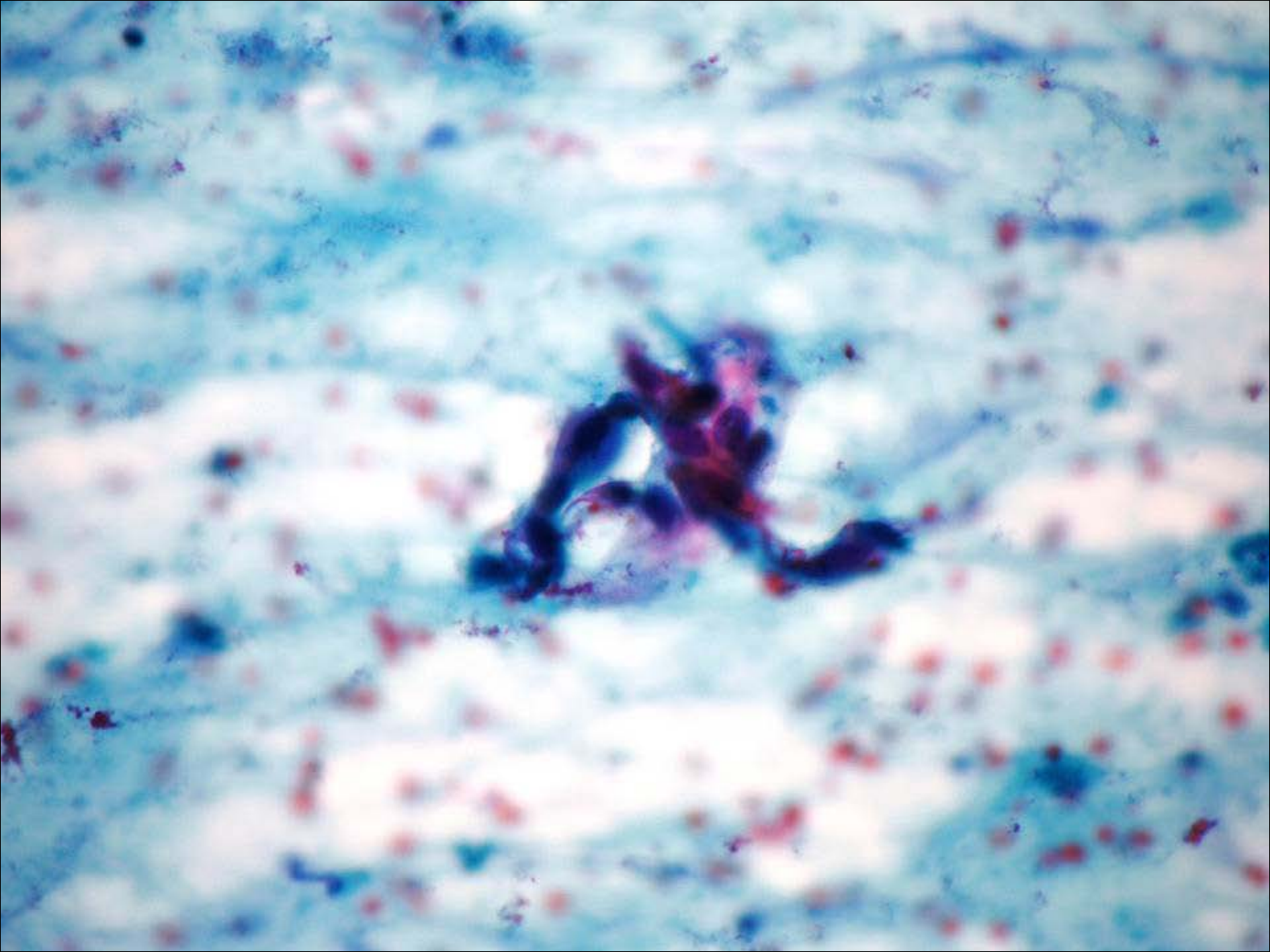


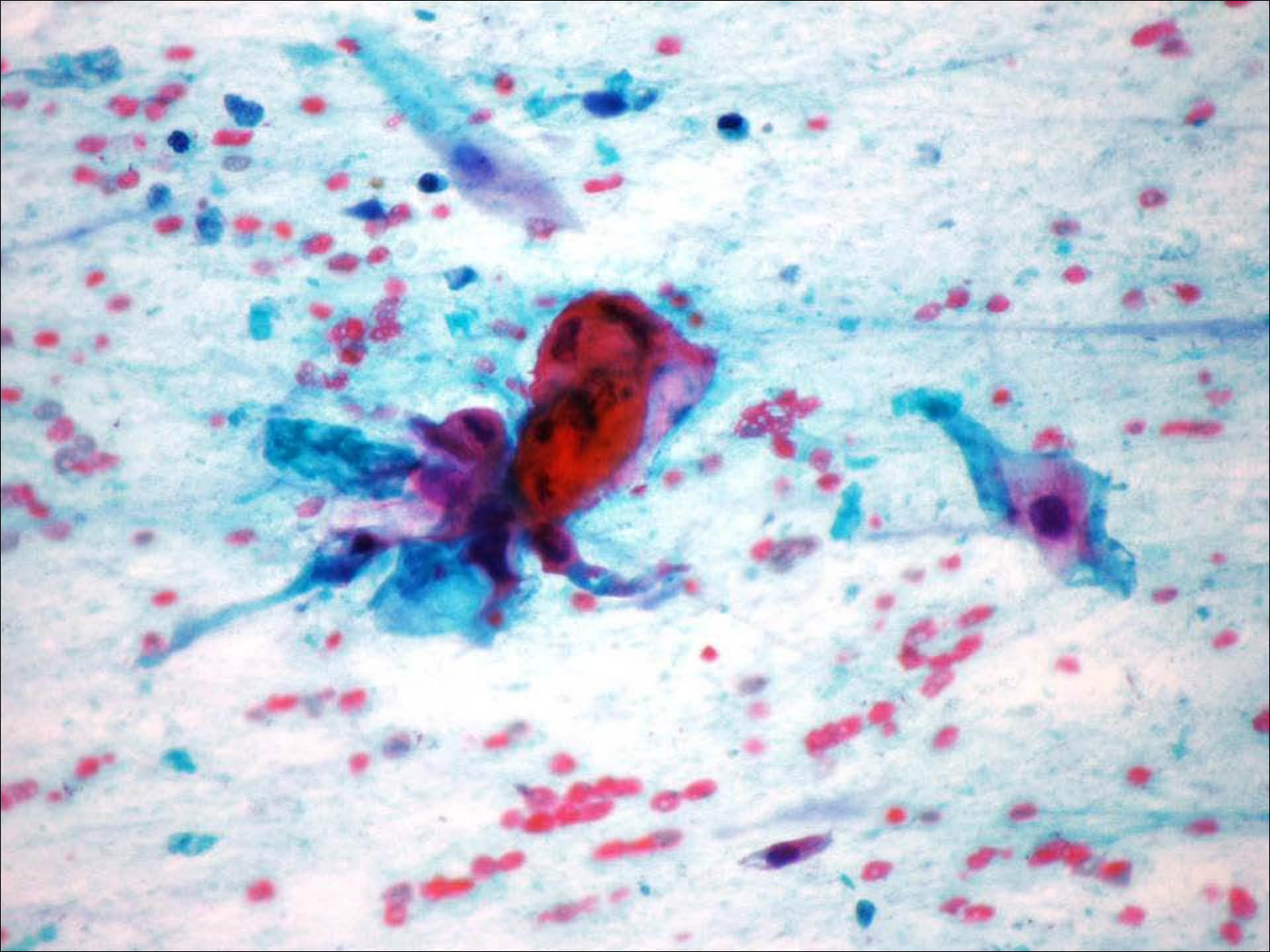












Cytologic Diagnosis:

Malignancy

Squamous cell carcinoma



Revised cytologic report

HSV infection with atypical squamous metaplasia.




細胞病理研討會

報告者：陳怡萍

Case Report

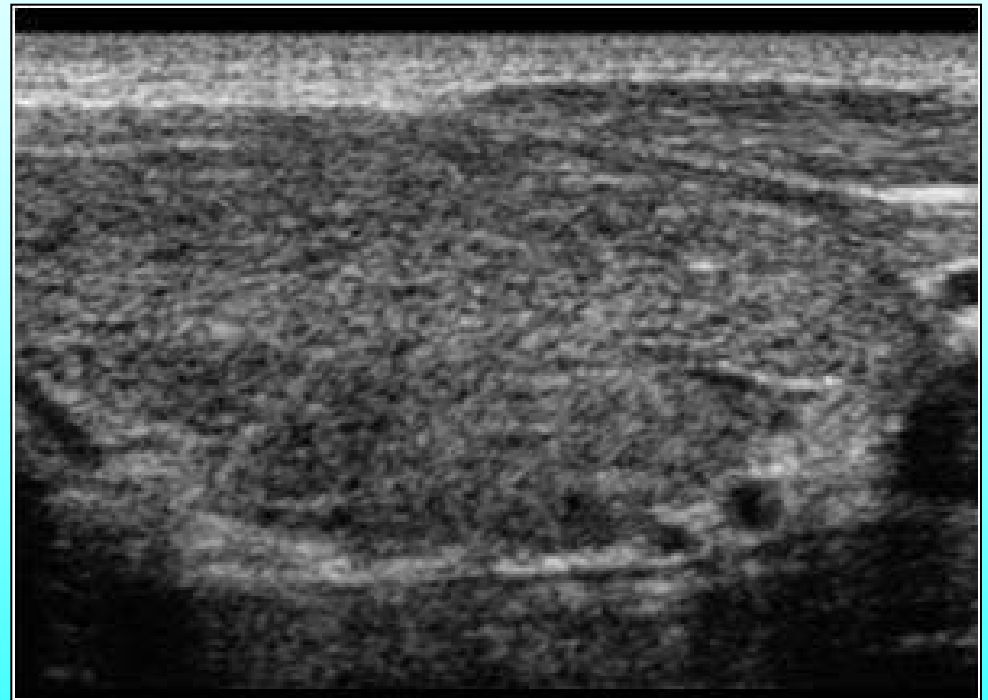
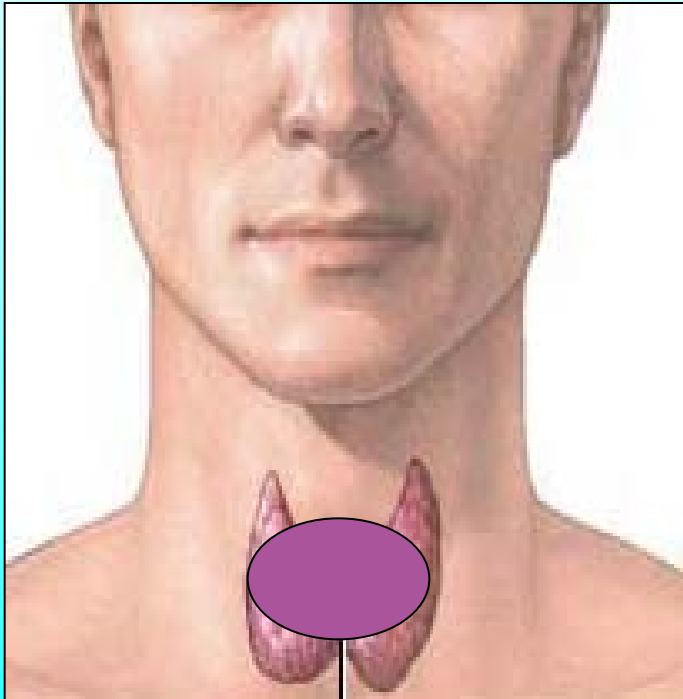
- **Present illness:**

A 47 y/o woman came to the Endocrine OPD with the problem of **body weight loss (9 kg for 6 months)**, insomnia, and **anterior neck enlarged** for about 3 months.



- **Physical examination:**

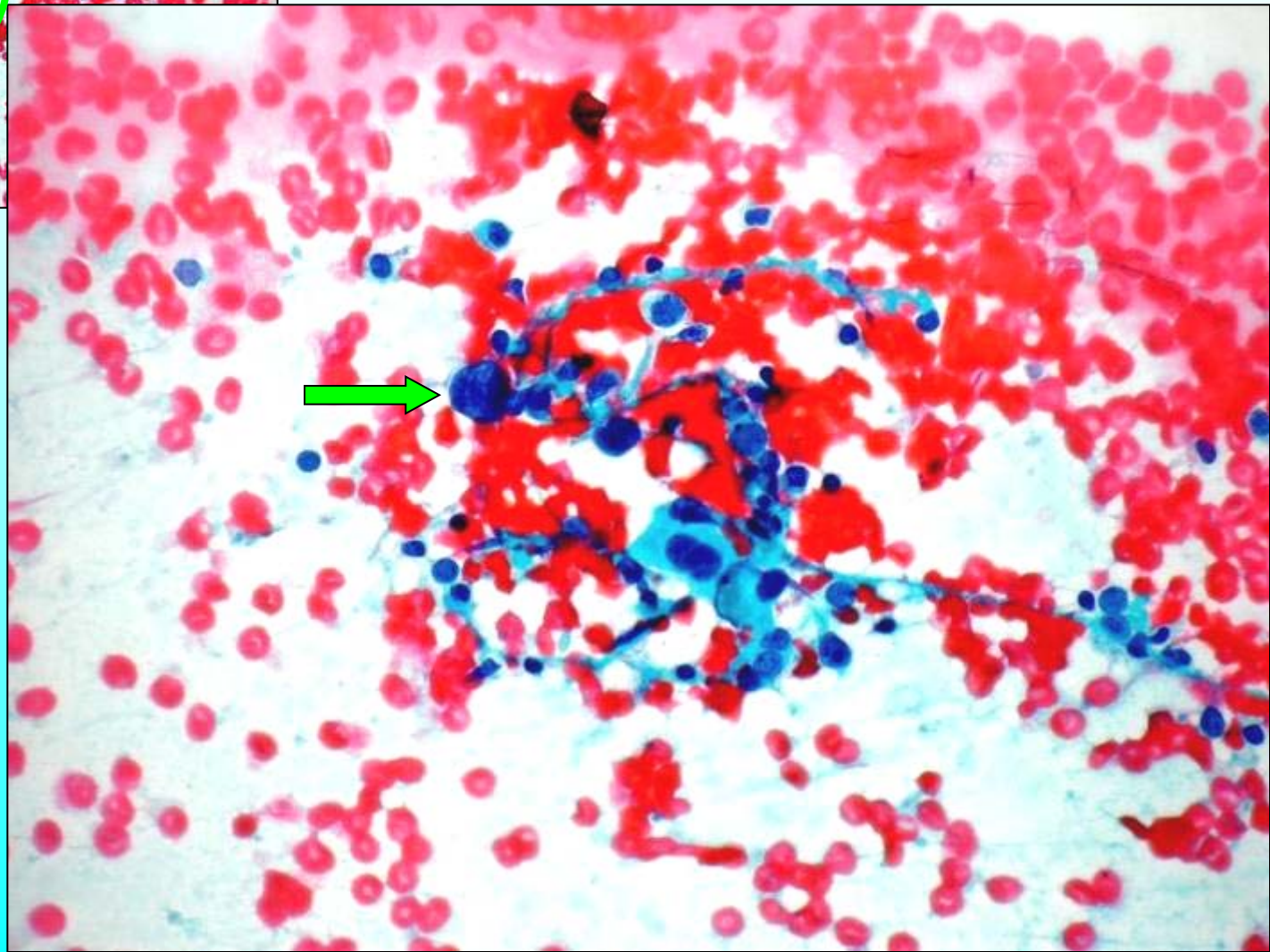
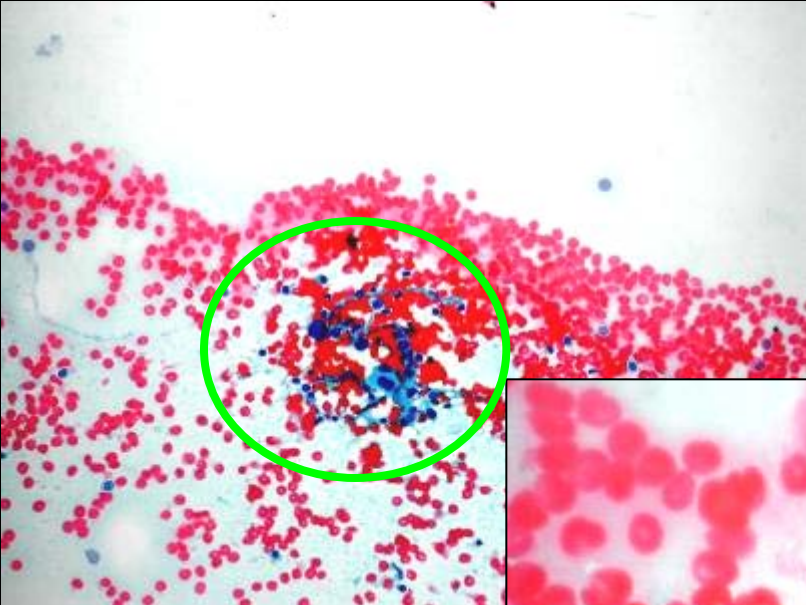
Anterior neck (thyroid) enlarged.

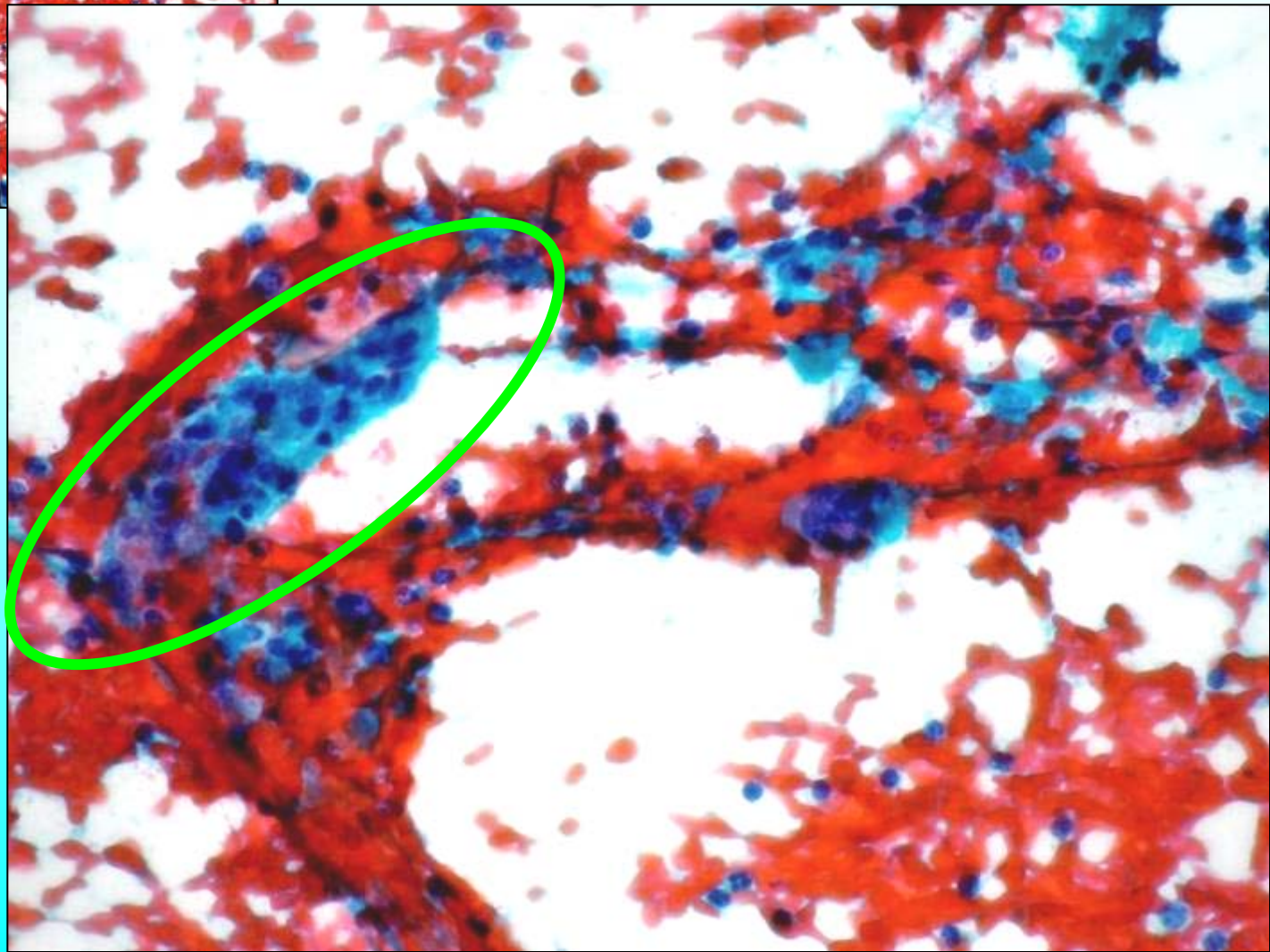
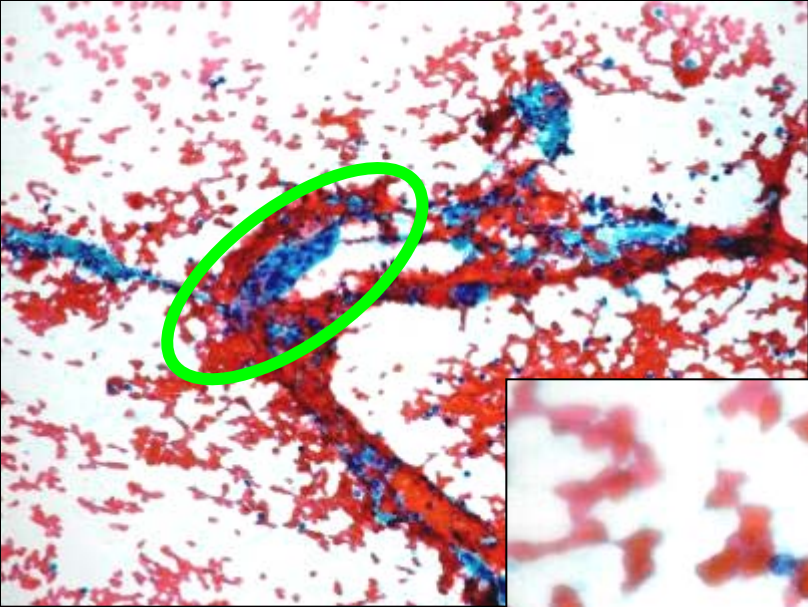


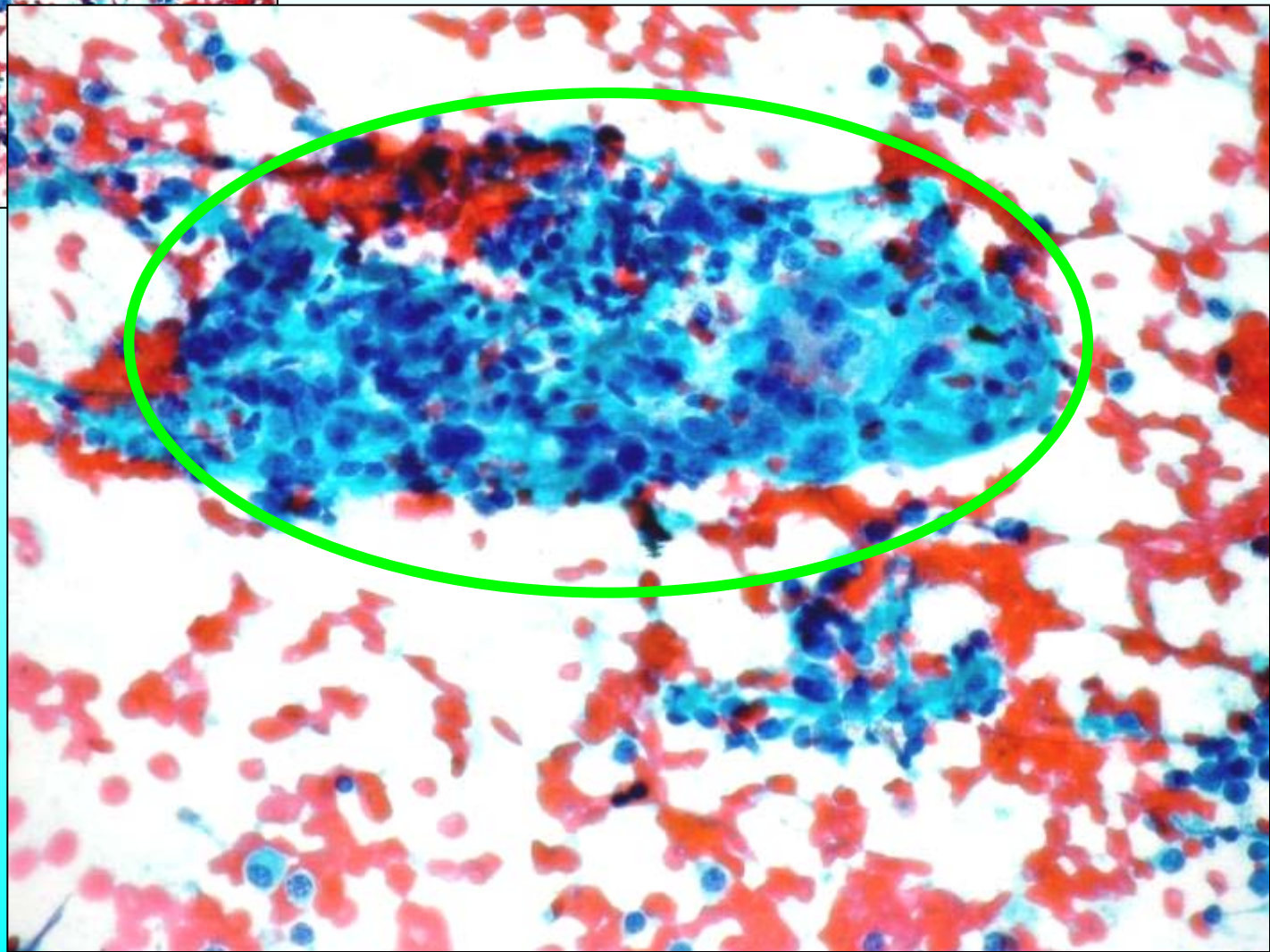
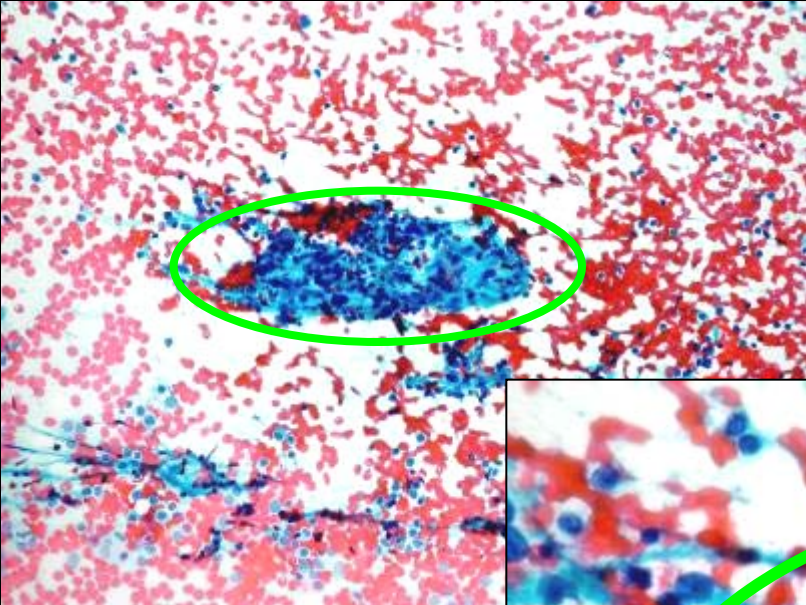
The bilateral thyroids show enlarged with heterogenous echogenicity.

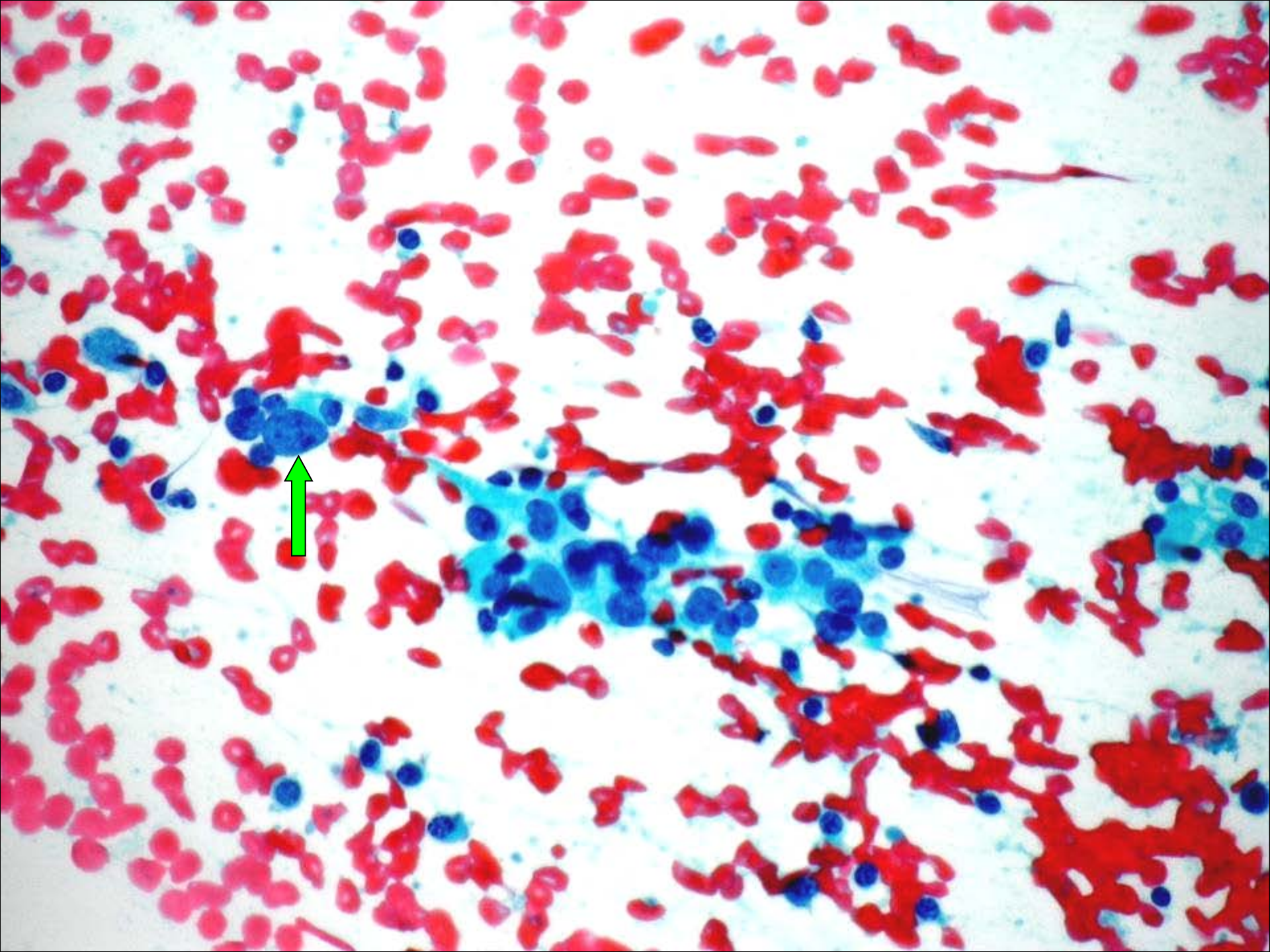
FNA of thyroid

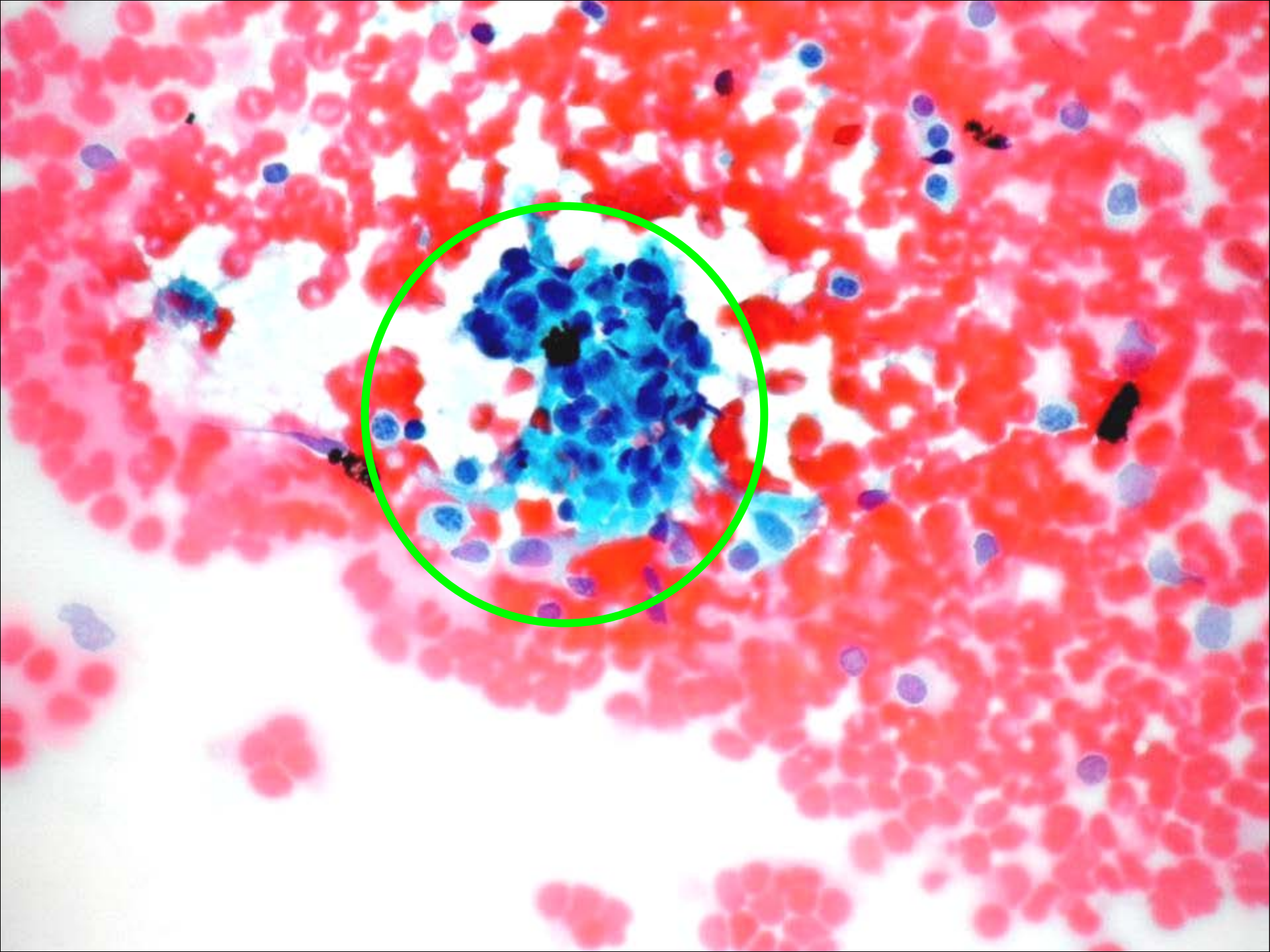
Pap stain

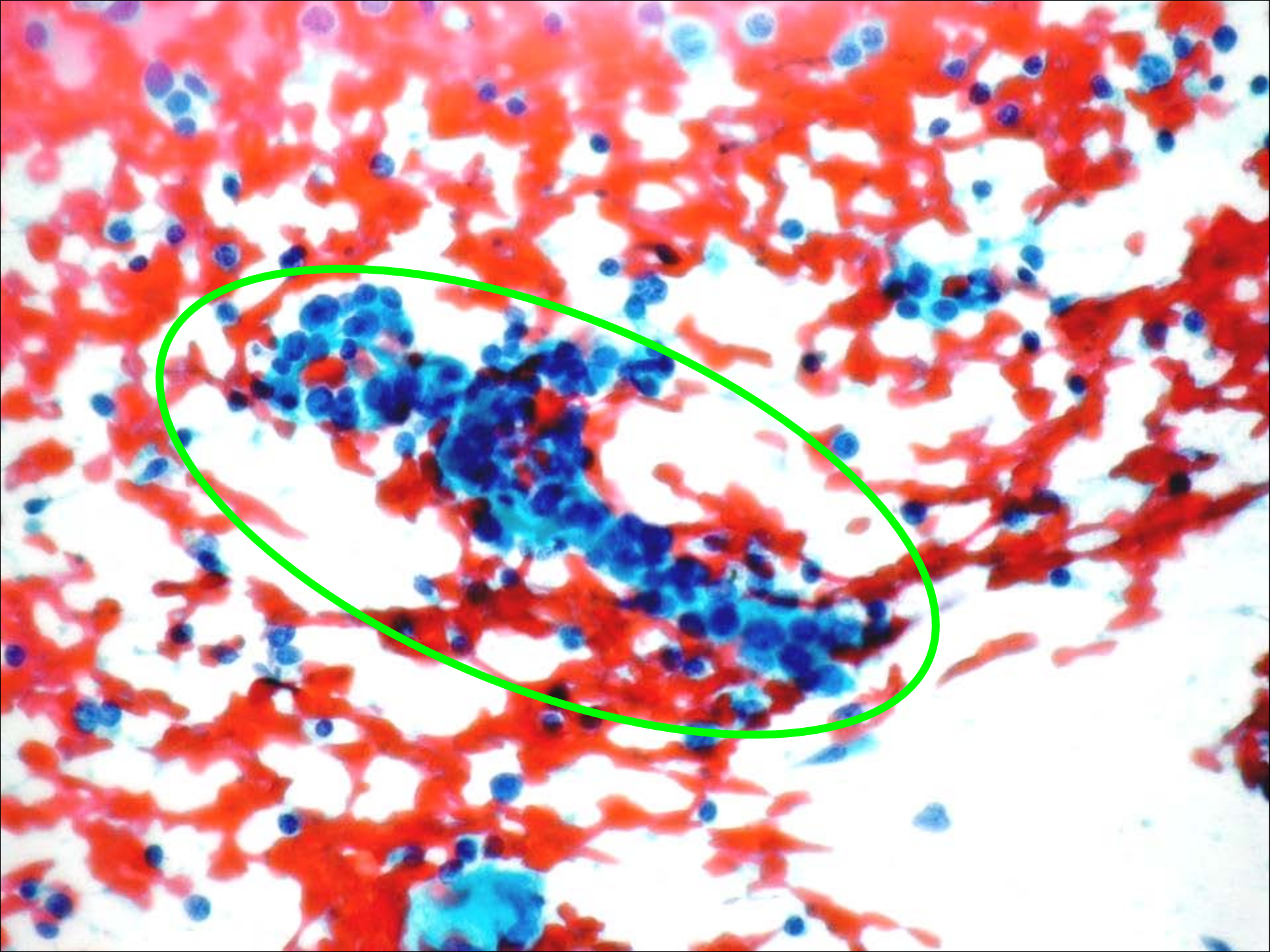


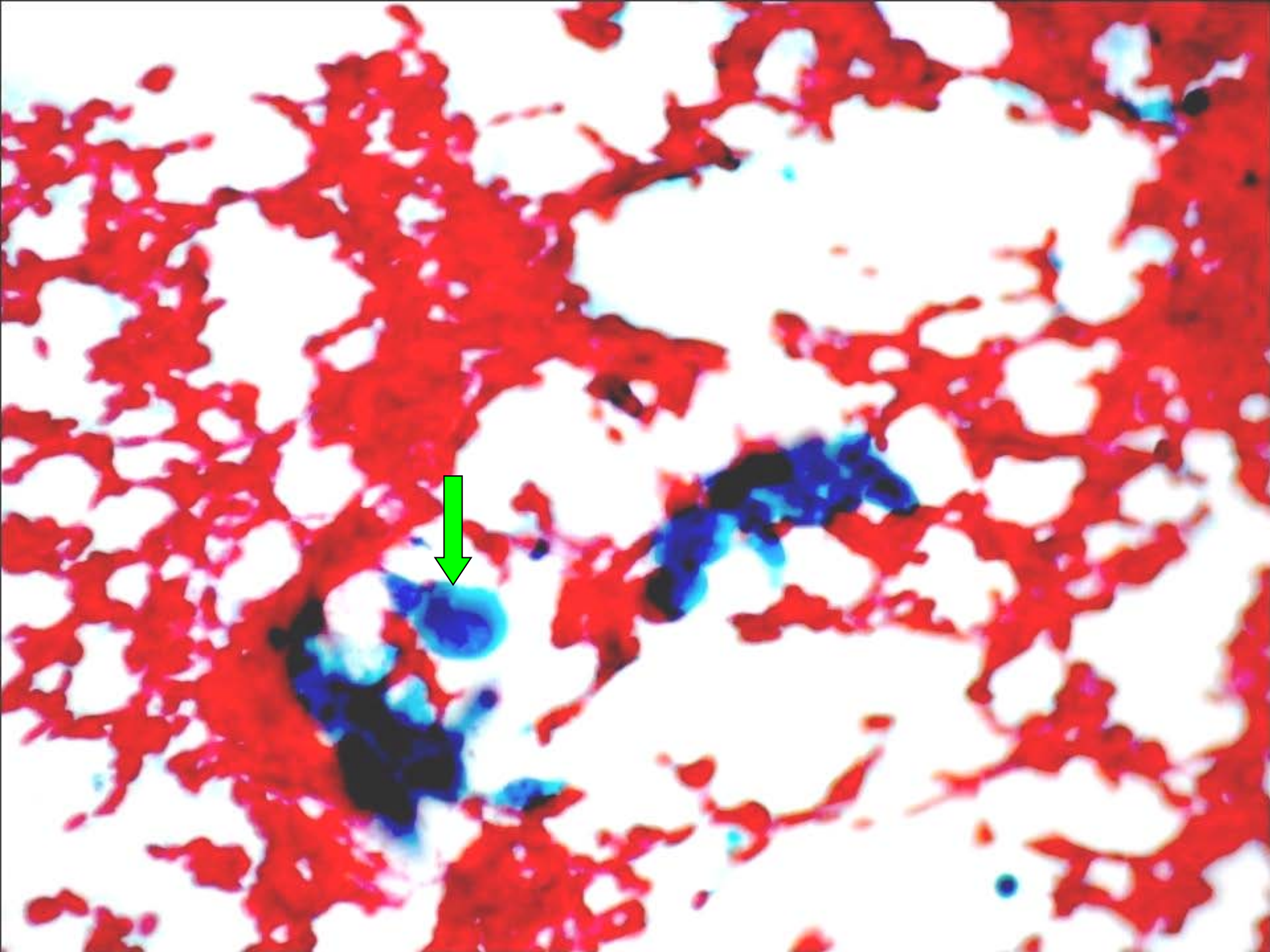


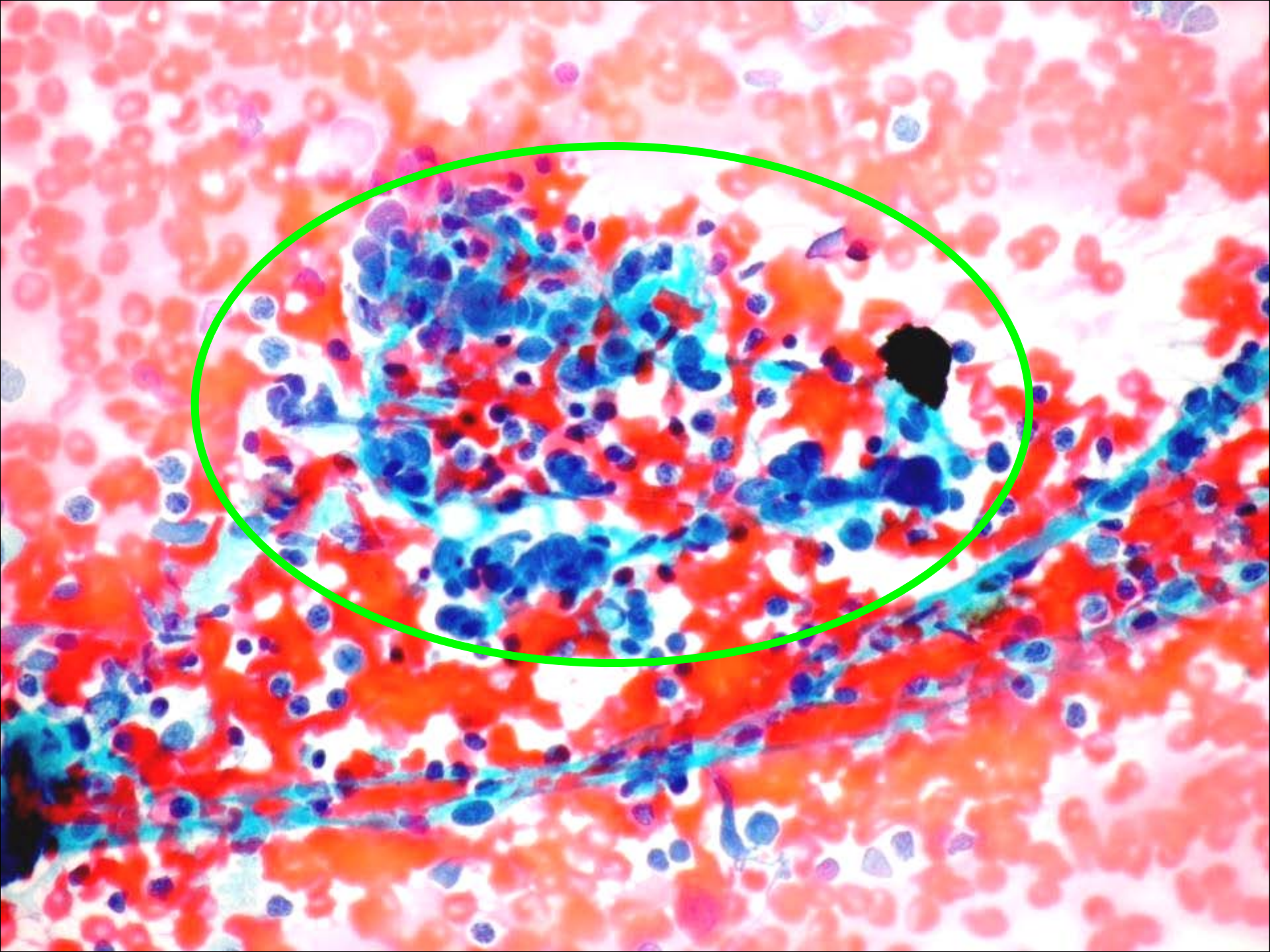












Cytology Diagnosis:

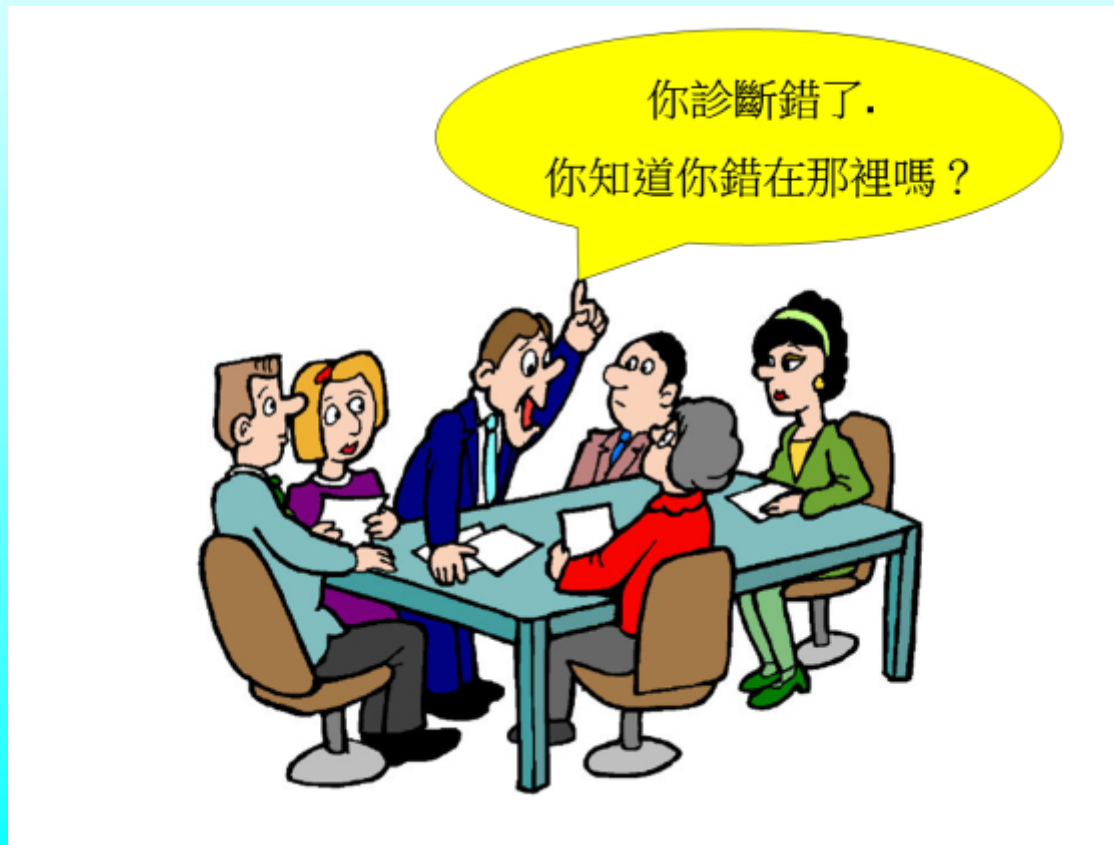Malignancy

Favor anaplastic carcinoma



Revised cytologic diagnosis:

Hashimoto's thyroiditis



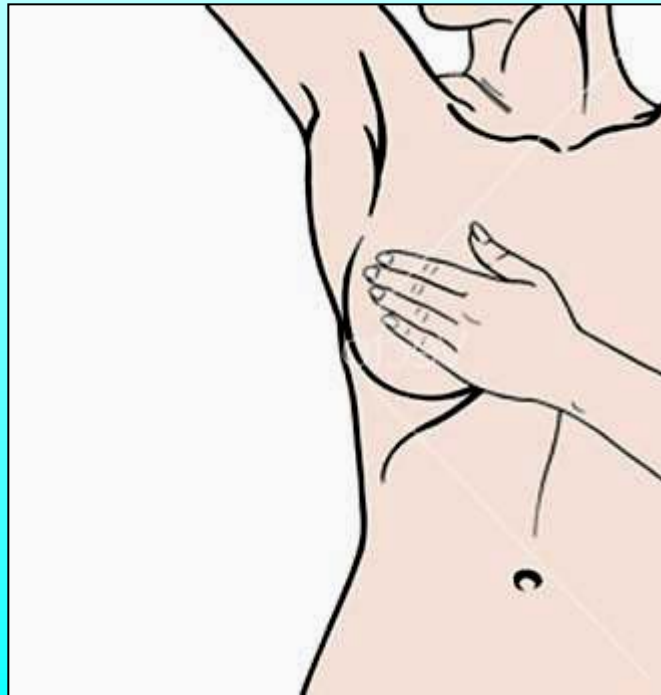細胞病理研討會

報告者：方錫泉

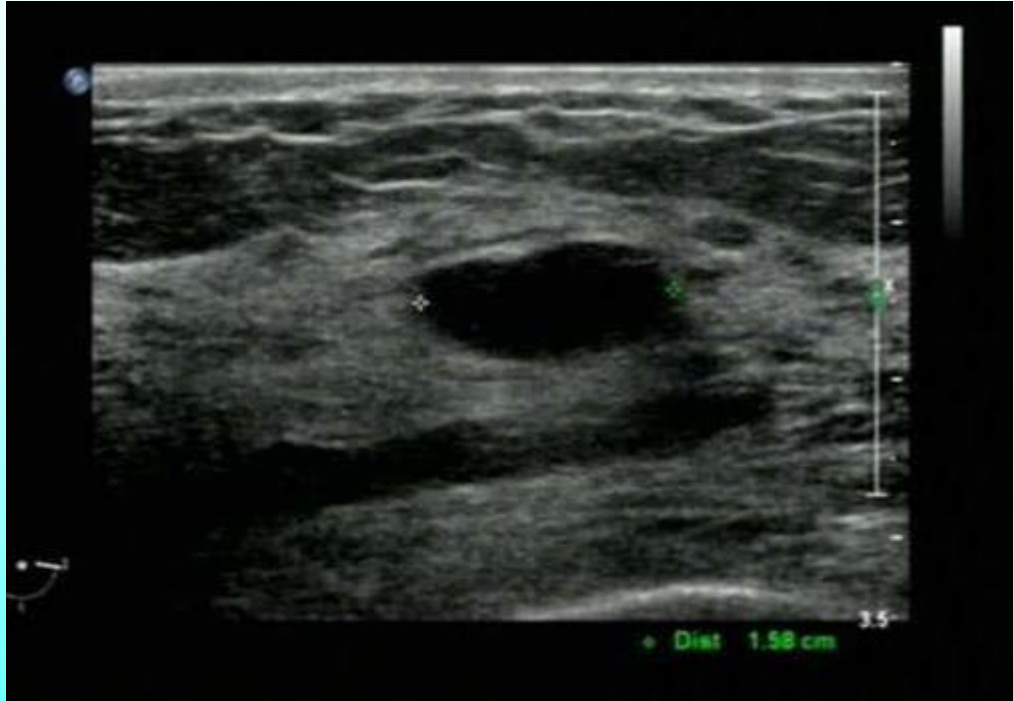Case report

Clinical history:

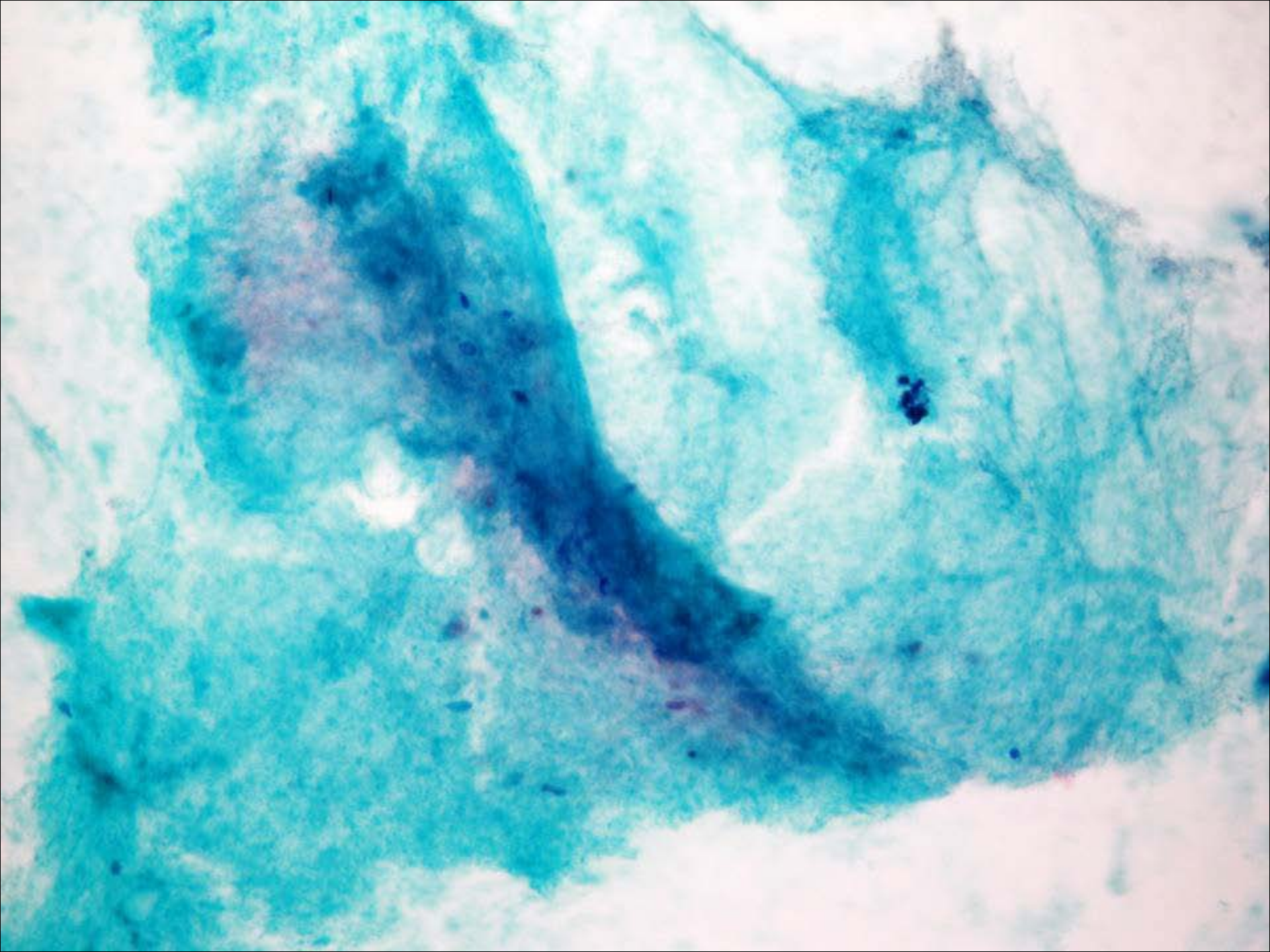
A 48 year-old female came to our GS OPD with the chief complaint of **palpable mass of right breast.**




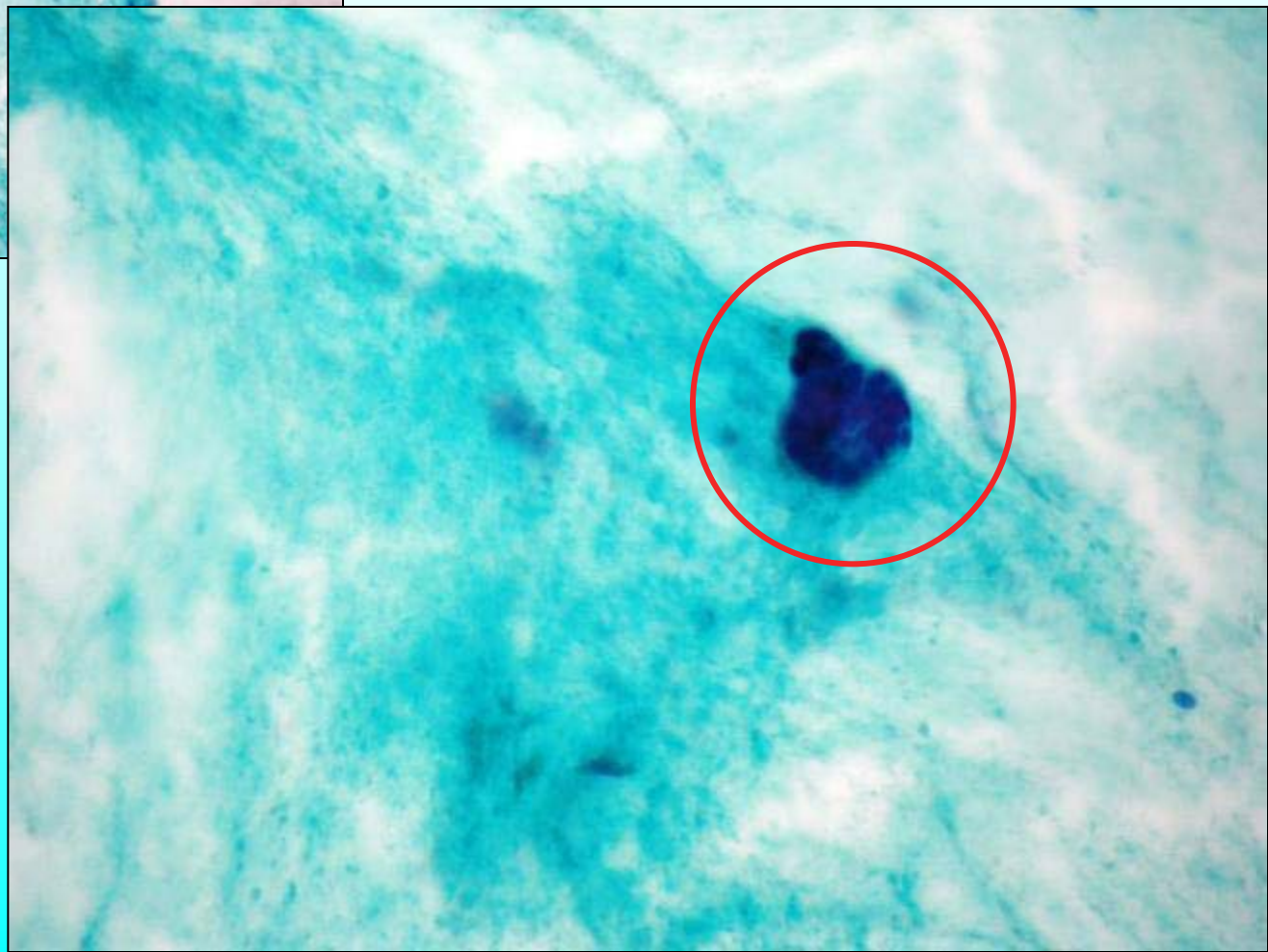
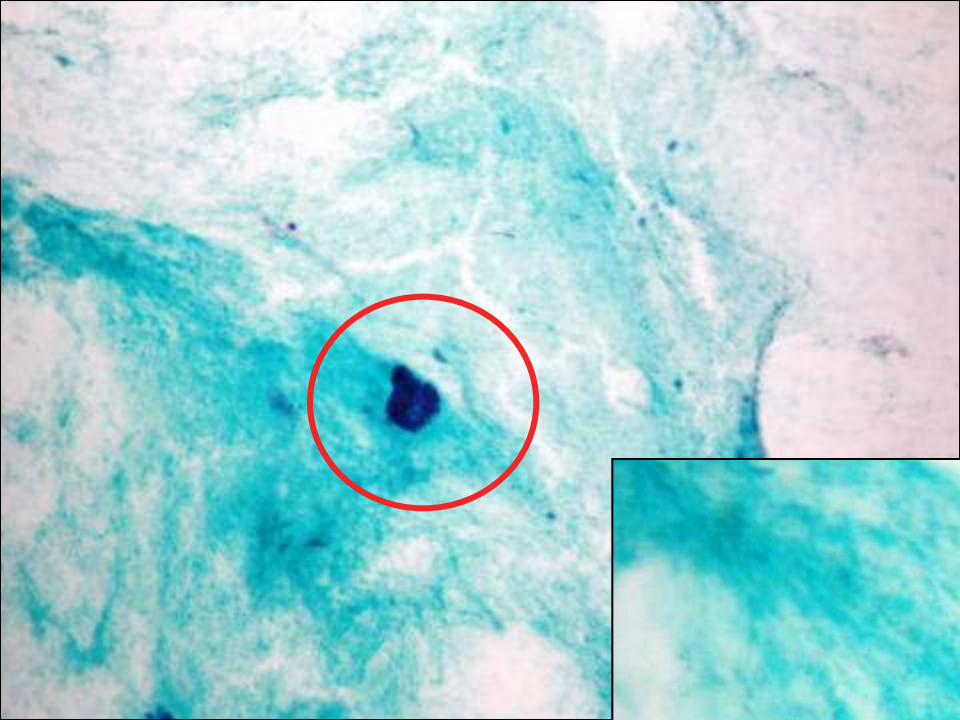
0
1 RMLO
8

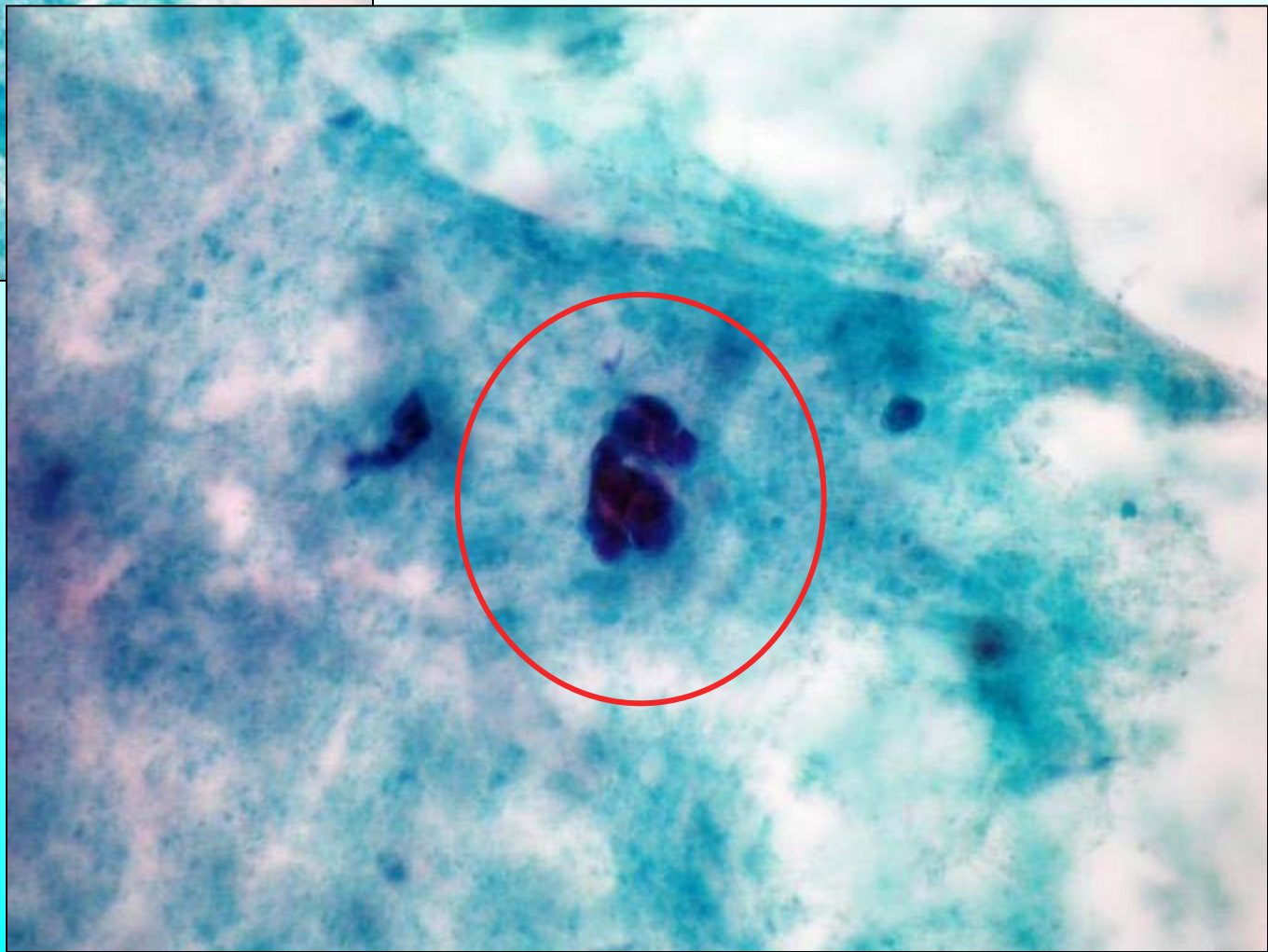
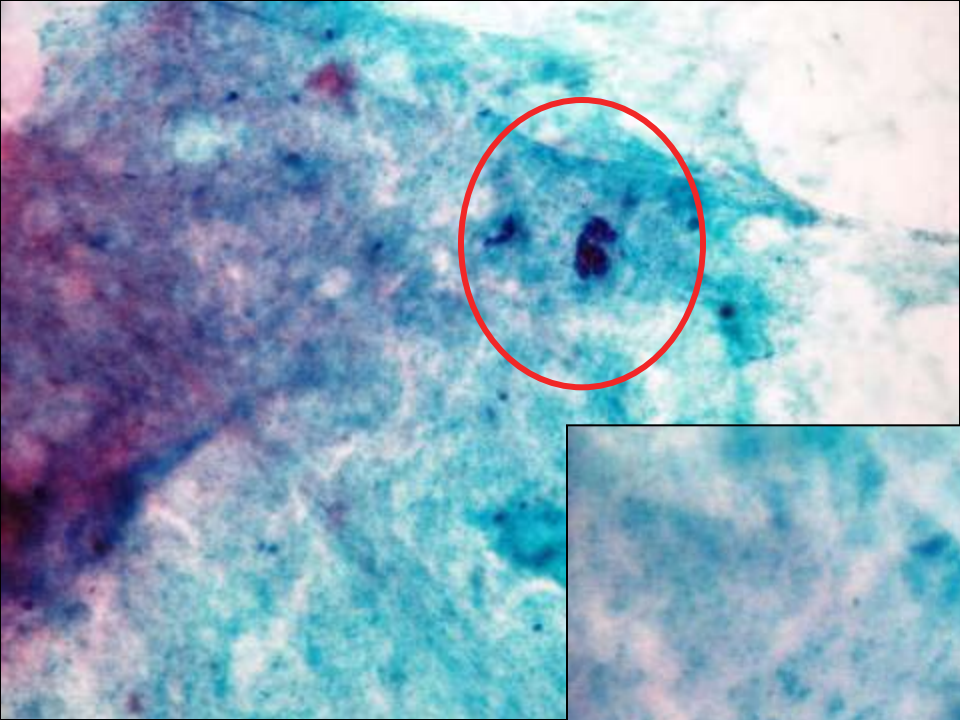


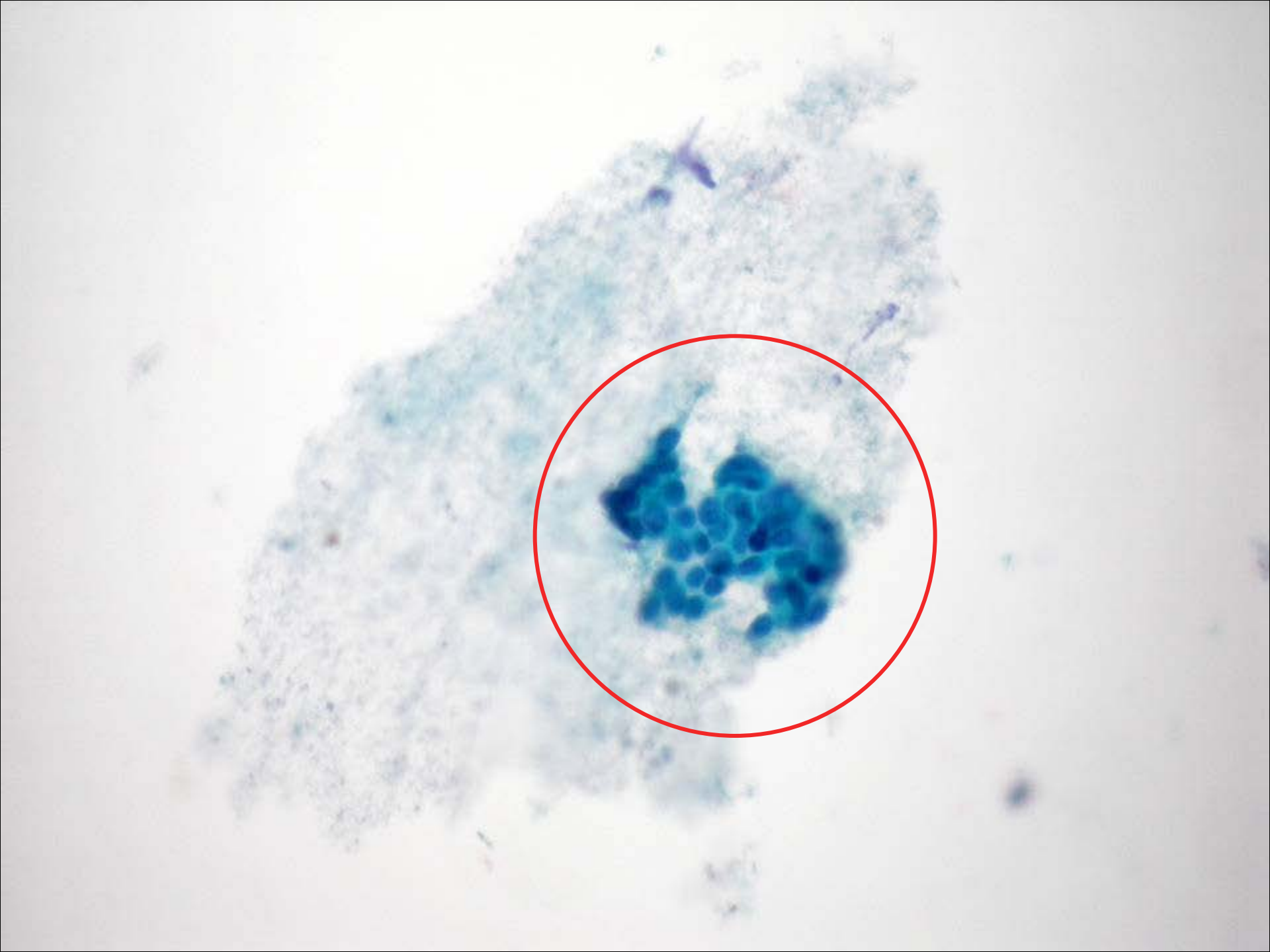- Aspiration cytology was performed under the clinical impression of breast tumor R/O colloid carcinoma.

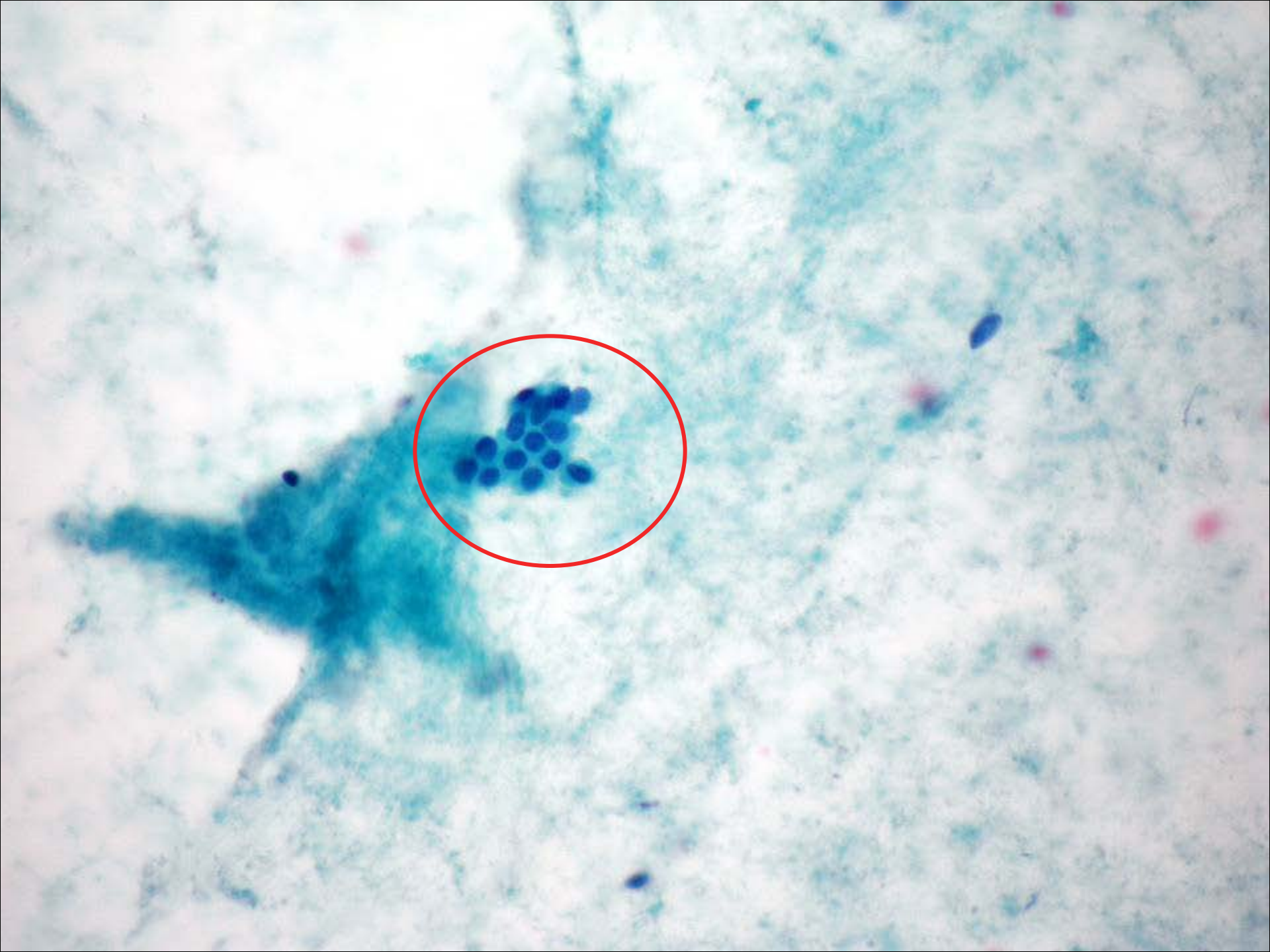


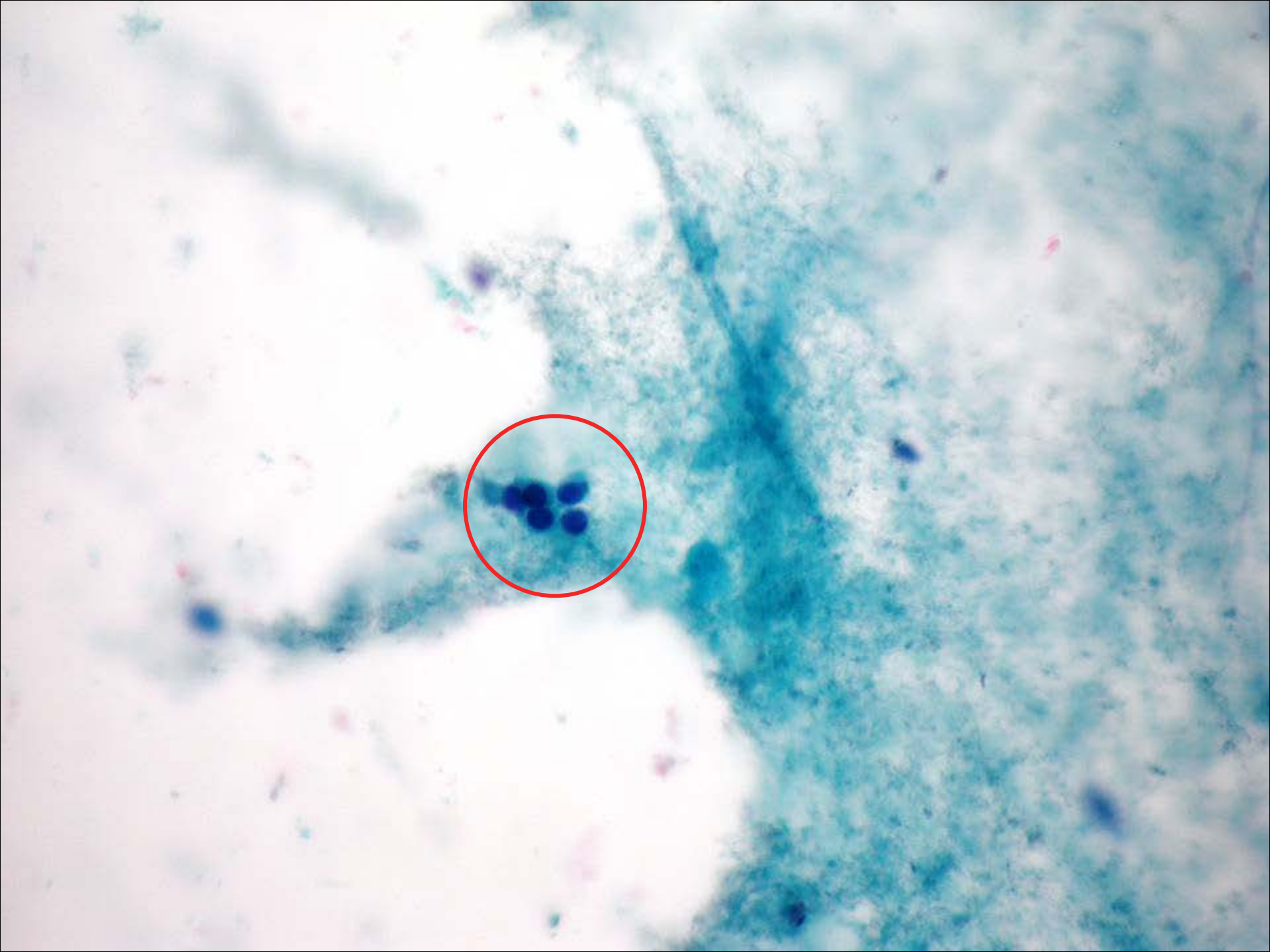

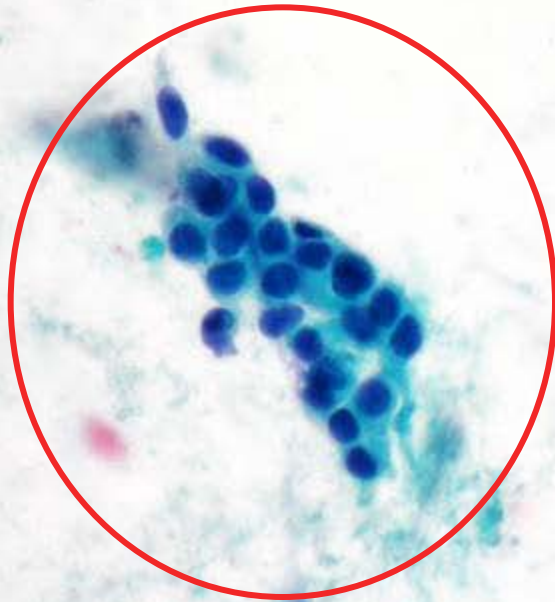






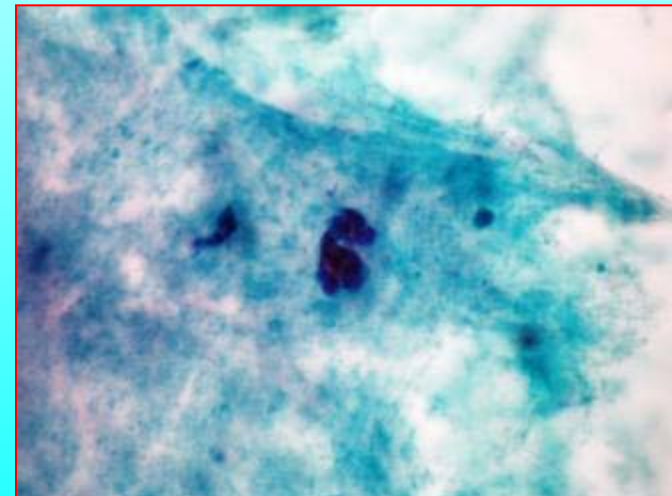
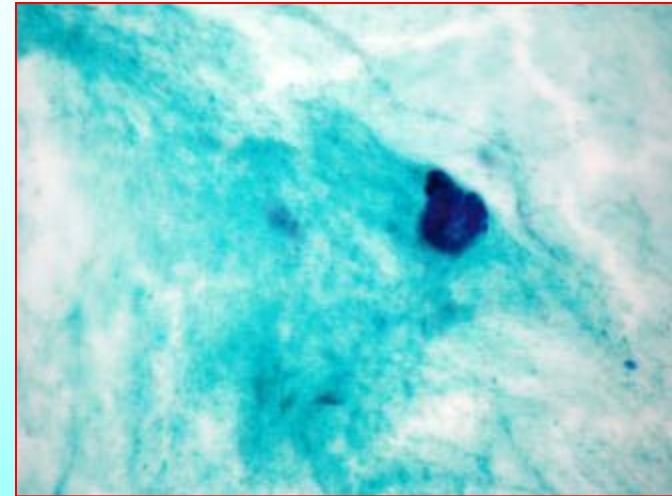






Cytologic findings

- Mucin background
- Monomorphic cell type
- Chromatin is fine, mild hyperchromasia
- Nuclei mild irregular in size and shape
- No necrosis



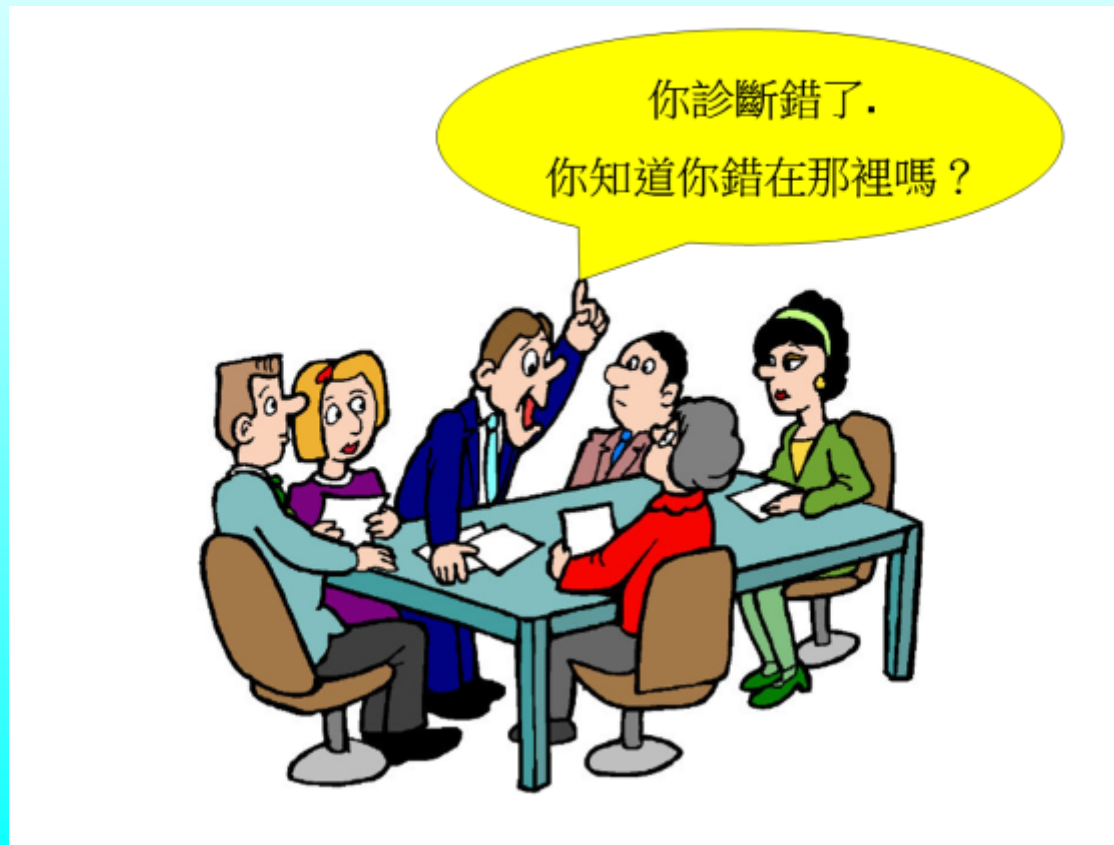Cytologic Diagnosis

Favor colloid carcinoma



Revised cytologic diagnosis:

Fibroadenoma



細胞病理研討會

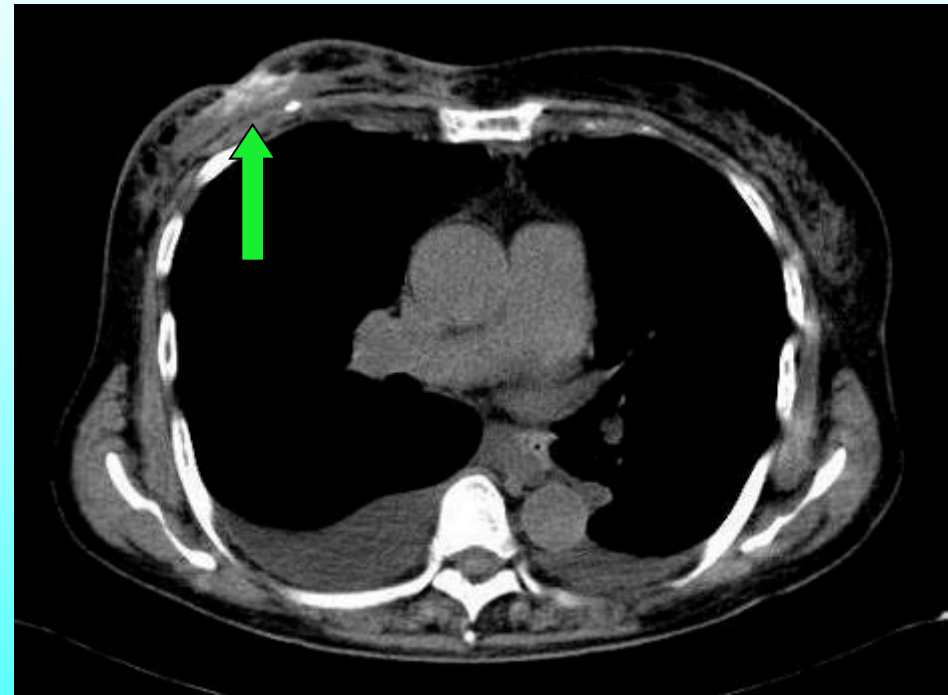
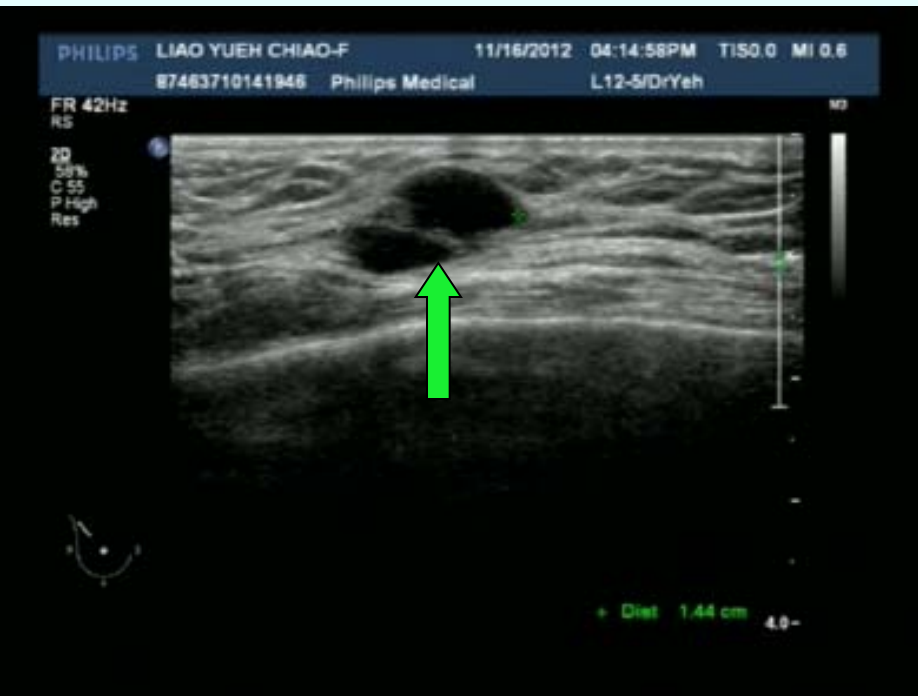
報告者：林綉瓊

Case report


- 66 y/o female, breast feeding (+), menopausal 49 y/o,
- She noticed a **painful mass** on the right breast with the covering skin showed ulcer with mild hemorrhage.

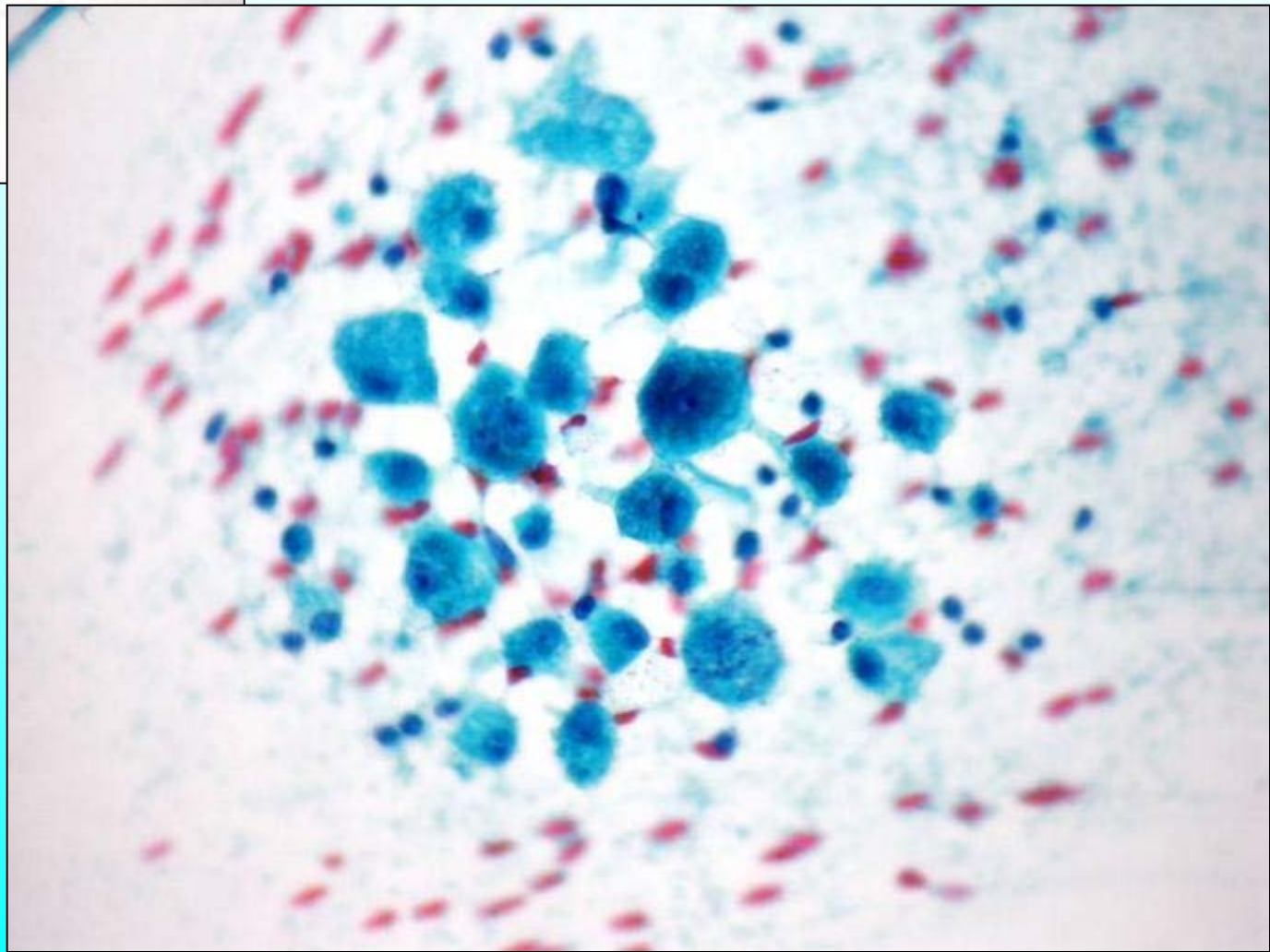
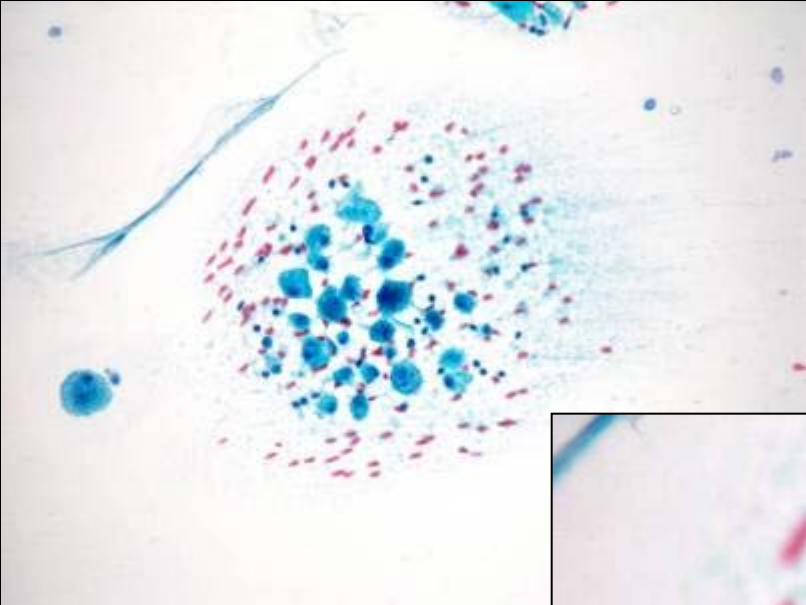


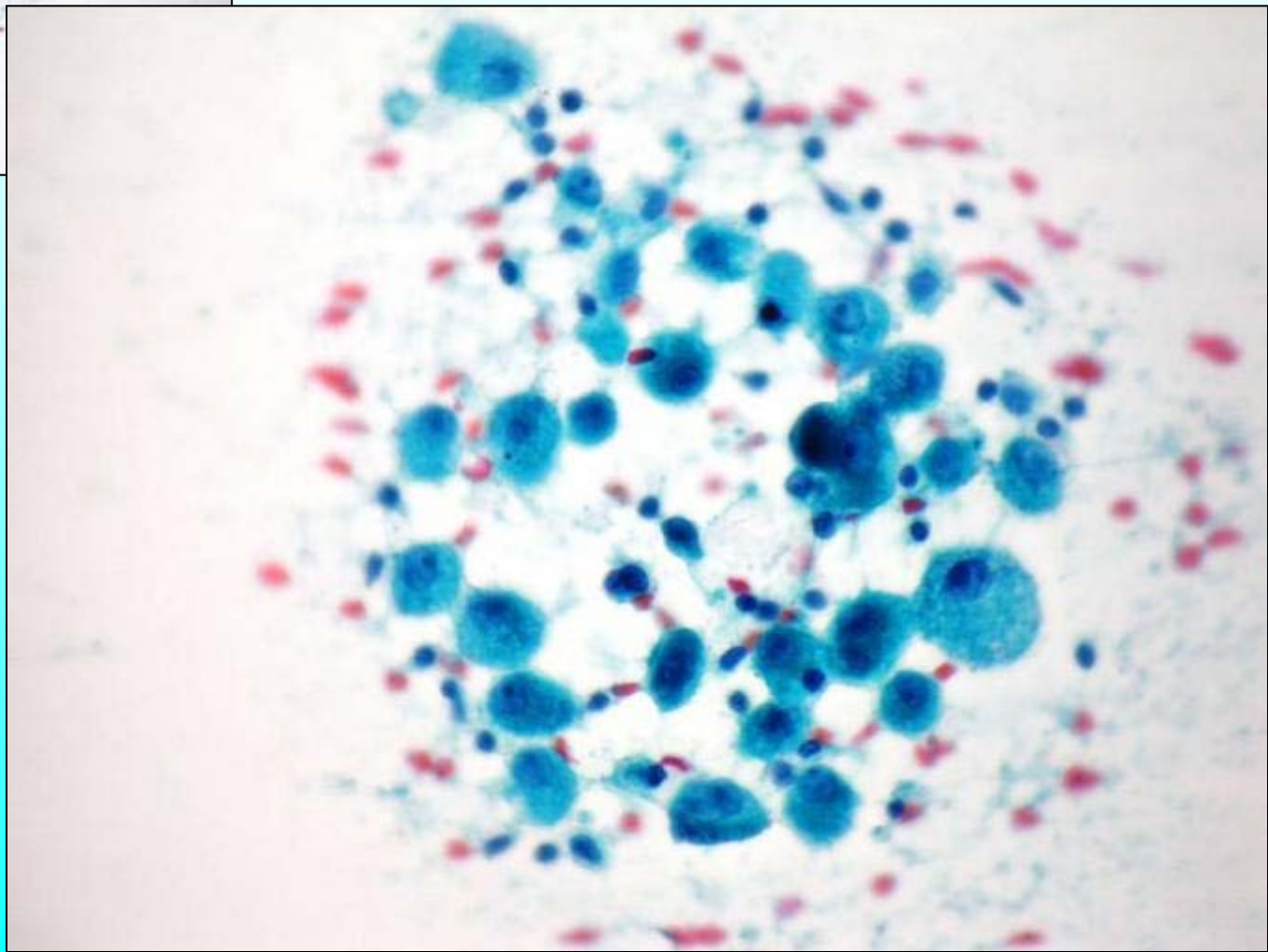
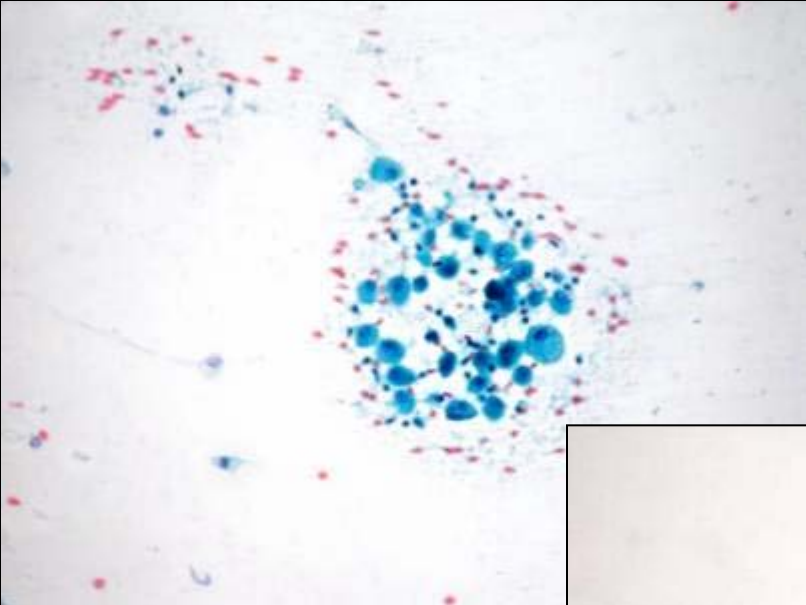
**Site: Right Location: 10.5 O'clock,
7 cm from nipple, 1 cm from skin,
size: 1.5 x 0.97 x 0.83 cm**

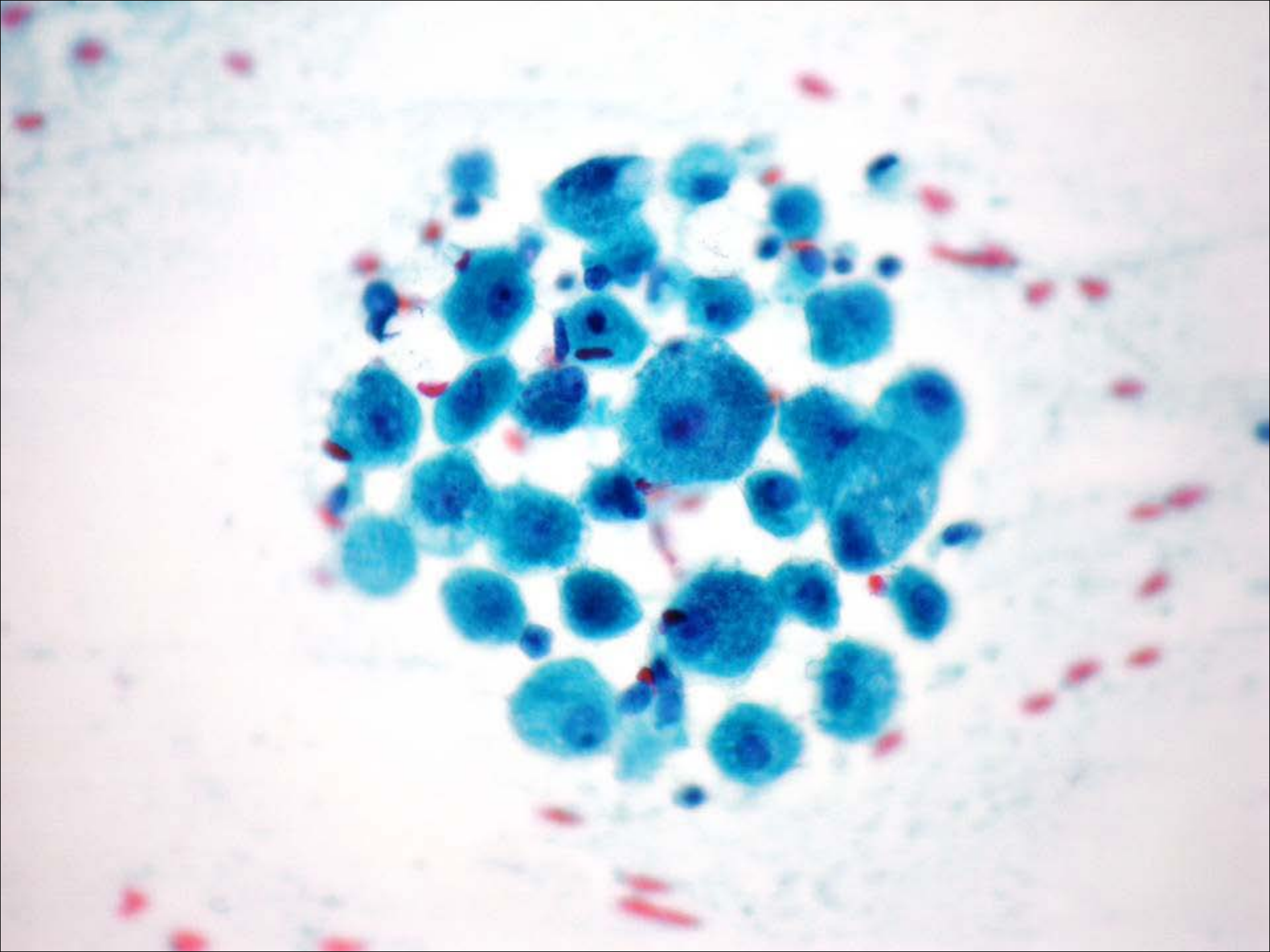


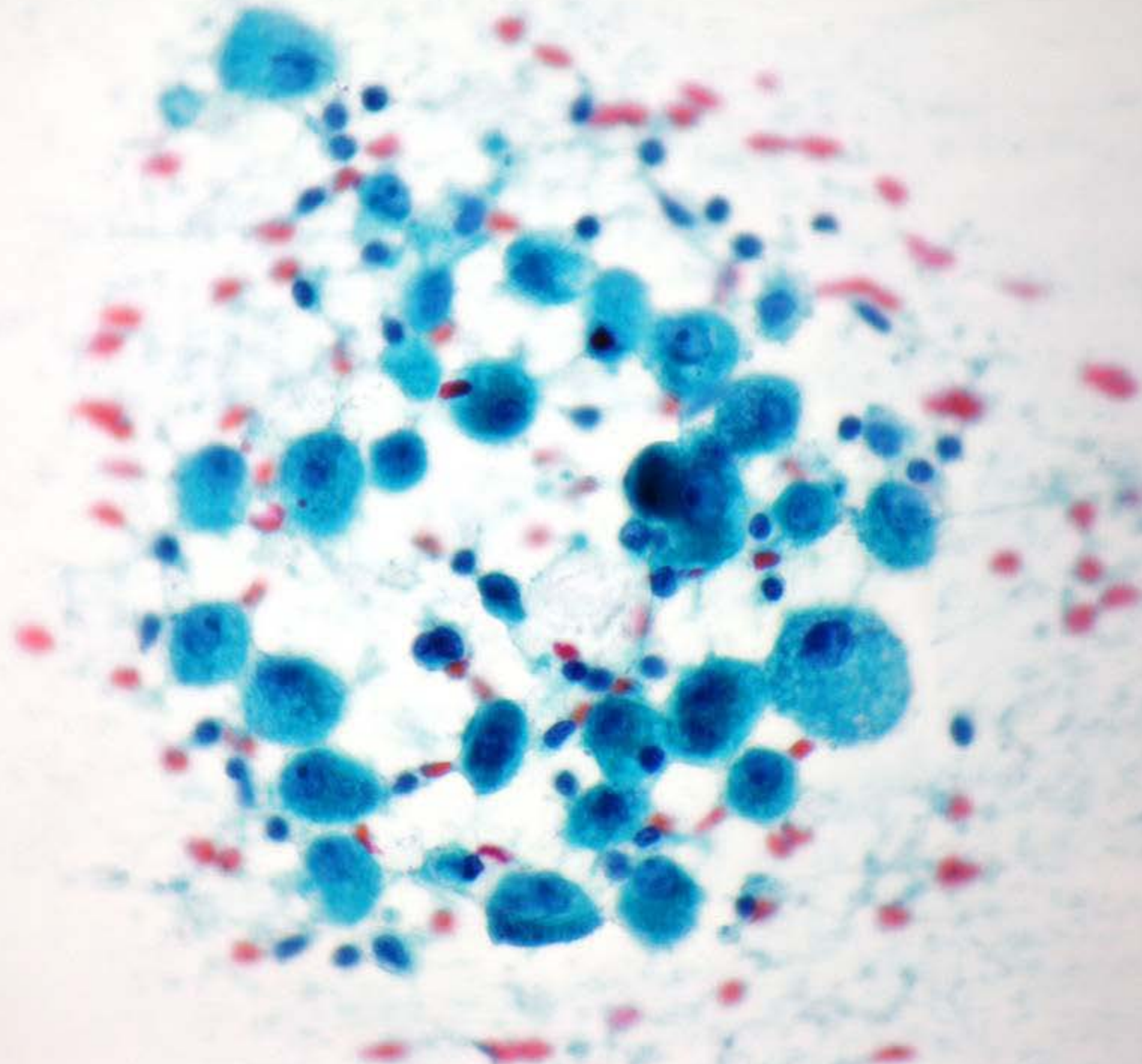
Breast aspiration cytology was performed











Cytologic Diagnosis:

Mastitis with abundant histiocytes



Revised cytologic diagnosis:

Apocrine carcinoma.



人非聖賢，孰能無過，過而能改，善莫大焉。

《左傳宣公二年》



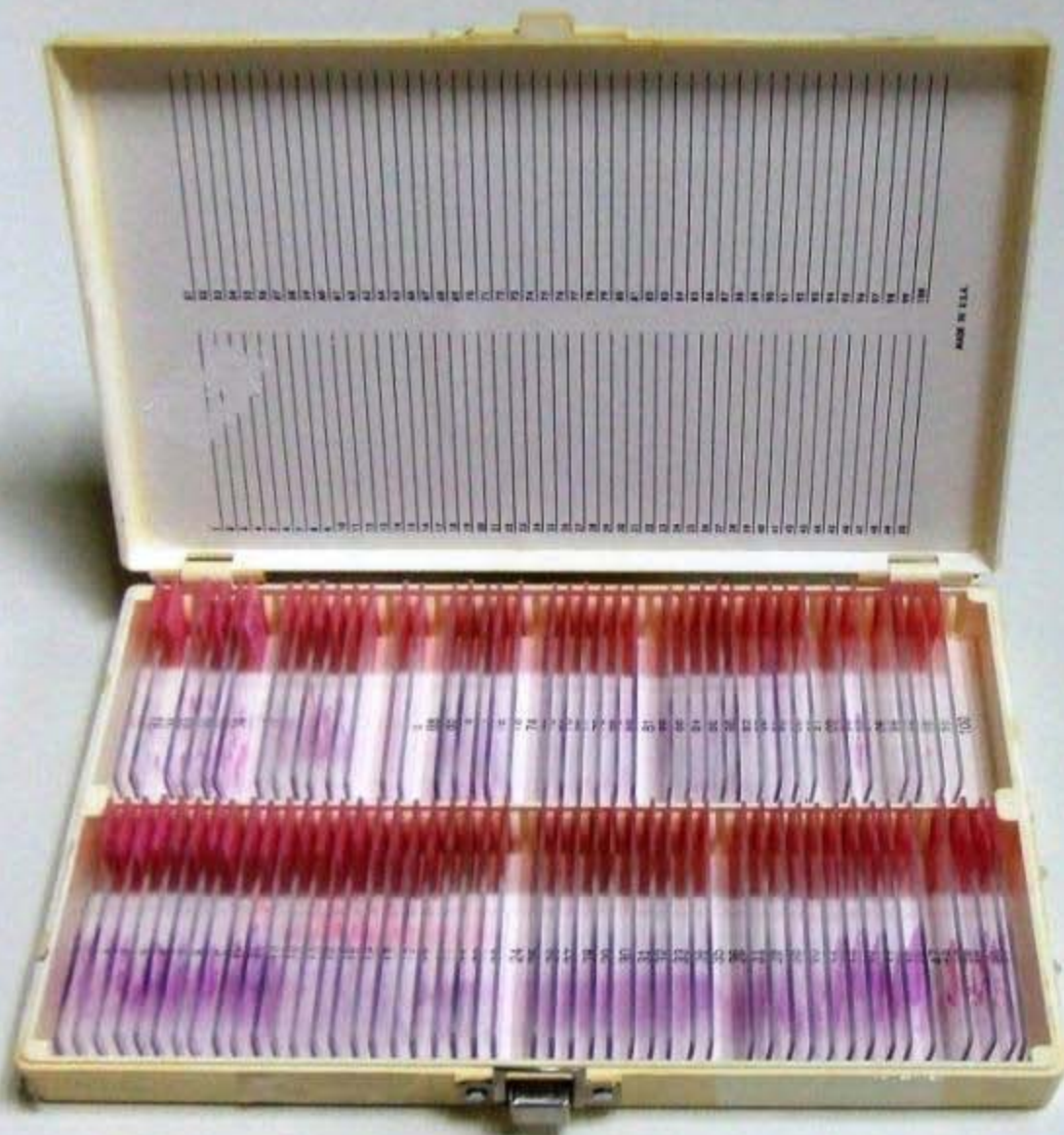To err is human ;

Every man has his faults ;

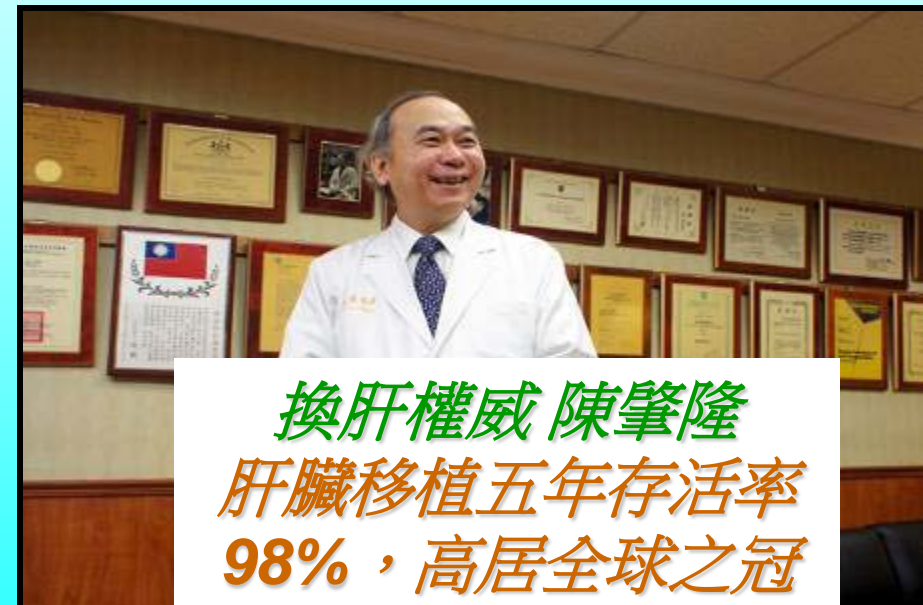Even Homer sometimes nods ;

All men but saints are apt to make mistakes.

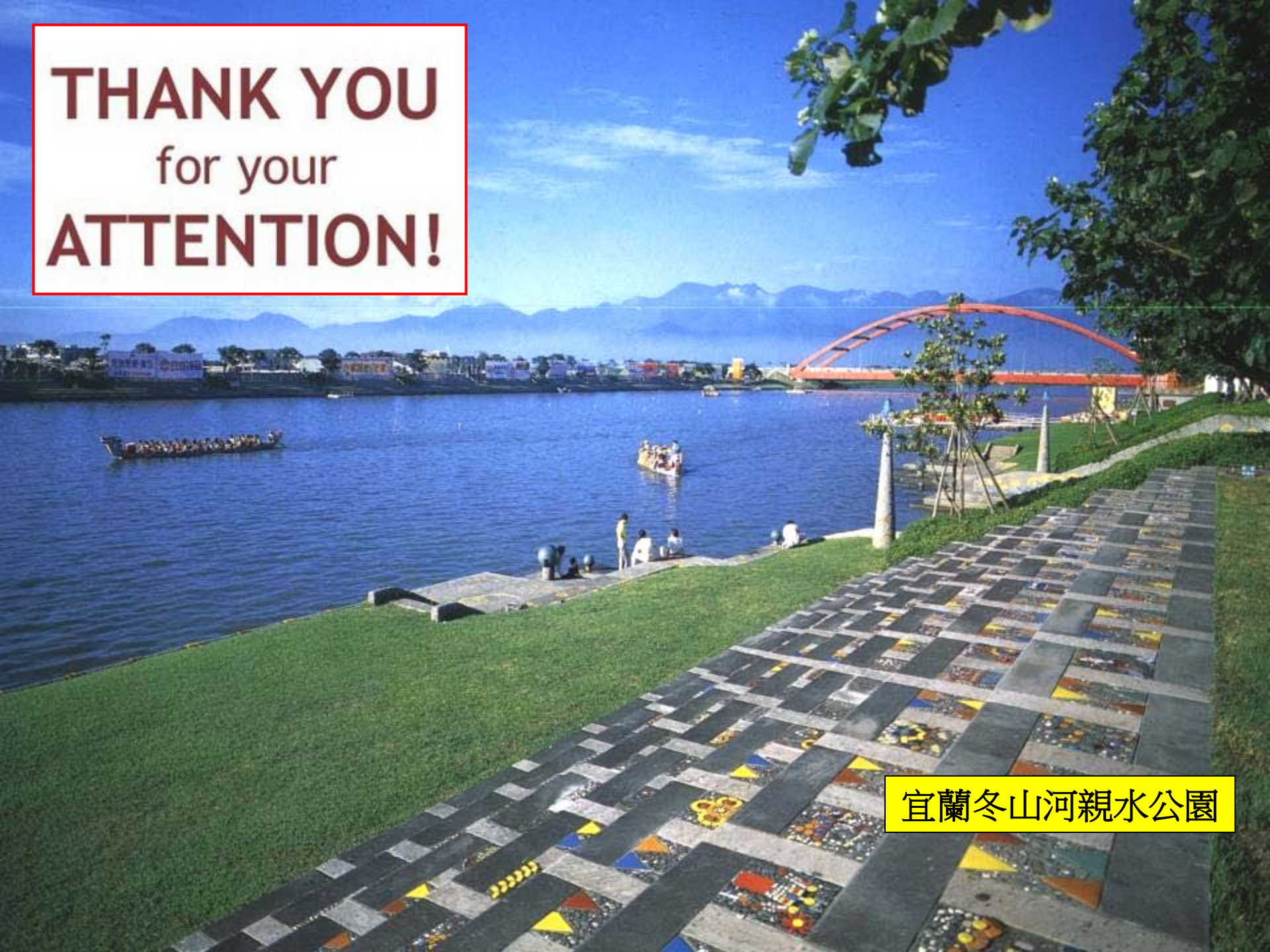收集罕見的或誤診的病理切片隨時提醒自己



- 準備一筆記本，記錄並追蹤病理結果，錯要知道錯在那裡，不斷精進成長，有朝一日您將成為最有權威的醫師。



THANK YOU
for your
ATTENTION!



宜蘭冬山河親水公園